

Received: 2015.10.14
Accepted: 2016.02.11
Published: 2016.06.28

Treatment of renal ANCA-associated vasculitides

Leczenie układowych zapaleń naczyń z przeciwciałami ANCA i zajęciem nerek

Olumide Olatubosun Rowaiye¹, Mariusz Kusztal¹, Wacław Weyde^{1,2,3}, Marian Klinger¹

¹Department of Nephrology and Transplantation Medicine, Wrocław Medical University, Wrocław, Poland

²Faculty of Dentistry, Wrocław Medical University, Wrocław, Poland

³Fresenius Polska

Summary

Antineutrophil cytoplasmic antibody (ANCA)-associated vasculitides (AAV) are a group of small vessel vasculitides which commonly affect the kidneys, manifesting as rapidly progressive glomerulonephritis. In this review, we present different treatment methods (e.g. cyclophosphamide, rituximab, plasma exchange) used for remission induction and maintenance in renal AAV. We also discuss treatment options in relapsing and refractory disease and for patients with end-stage renal disease due to AAV. In addition, we enumerate the various risk factors associated with relapsing and refractory disease, quality of life impairment and decreased renal and patient survival in AAV. Finally we present information on new, potentially applicable agents which can further help modify the disease course, thereby leading to increased patient survival.

Key words: Antineutrophil cytoplasmic antibody (ANCA)-associated vasculitides • glomerulonephritis • outcome • relapse • treatment

Full-text PDF: <http://www.phmd.pl/fulltxt.php?ICID=1207508>

Word count: 6369
Tables: 3
Figures: 1
References: 120

Author's address: Olumide O. Rowaiye, MD, Department of Nephrology and Transplantation Medicine, Wrocław Medical University, Borowska 213, 50-556 Wrocław, Poland; e-mail: oluowe@yahoo.com



List of abbreviations:

AAV– ANCA-associated vasculitides, **AGP**– alpha-1 acid glycoprotein, **ANCA**–antineutrophil cytoplasmic antibody, **ATG**–antithymocyte globulin, **BAFF**– B-cell activating factor belonging to tumor necrosis family, **BHPR**– British Health Professionals in Rheumatology, **BlyS**– B-lymphocyte stimulator, **BSR**– The British Society for Rheumatology, **BTZ** – bortezomib, **BVAS**– Birmingham Vasculitis Activity Score, **CCL18**– CC chemokine ligand 18, **CRP**– C-reactive protein, **CY** – cyclophosphamide, **DSG**– 15-deoxyspergualin, **eGFR**– estimated glomerular filtration rate, **EGPA**– eosinophilic granulomatosis with polyangiitis, **ELISA**– enzyme-linked immunosorbent assay, **ESRD**– end-stage renal disease, **EUVAS**– the European Vasculitis Society (formerly the European Vasculitis Study Group), **GPA**– granulomatosis with polyangiitis, **IgG**– immunoglobulin G, **IIF**– indirect immunofluorescence, **IV-CY**– intravenous cyclophosphamide, **IVIG**– intravenous immunoglobulin, **KIM-1**– kidney injury molecule-1, **MCP-1**– monocyte chemoattractant protein-1, **MMF** – mycophenolate mofetil, **MPA**– microscopic polyangiitis, **MPO** – myeloperoxidase, **MTX** – methotrexate, **NGAL**– neutrophil gelatinase-associated lipocalin, **PCT** – procalcitonin, **PLEX**– plasma exchange, **PML**– progressive multifocal leukoencephalopathy, **PR3**– proteinase-3, **QOL**– quality of life, **RLV**– renal-limited vasculitis, **RPGN** – rapidly progressive glomerulonephritis, **RTX**–rituximab, **SF-36**– short form 36, **Syk**– spleen tyrosine kinase, **VDI**– vasculitis damage index.

INTRODUCTION

Antineutrophil cytoplasmic antibody (ANCA)-associated vasculitides (AAV) are a group of small vessel vasculitides which are characterized by the presence of ANCA in the circulation (although it should be noted that some patients have no circulating ANCA [i.e. are ANCA-negative] but have similar disease manifestations as those who are ANCA-positive) [22,48].

ANCA are autoantibodies directed against cytoplasmic antigens on neutrophils and monocytes. The most common antigenic targets for ANCA are proteinase-3 (PR3) and myeloperoxidase (MPO) [29,48]. ANCA is detected using indirect immunofluorescence (IIF) and enzyme-linked immunosorbent assay (ELISA) methods [93]. ANCA has been implicated in the pathogenesis of AAV [47]. AAV types include microscopic polyangiitis (MPA), granulomatosis with polyangiitis (GPA, formerly called Wegener's granulomatosis), eosinophilic granulomatosis with polyangiitis (EGPA, formerly Churg-Strauss syndrome) and renal-limited vasculitis (RLV) [48].

Although AAV can occur at any age, it typically occurs between the fifth and seventh decades of life, with a greater incidence in Caucasians than in people of African descent [48,78]. The estimated disease incidence for AAV is 15-23 per million population [76].

AAV can affect different organ systems of the body (e.g. the lungs, heart, kidneys, nervous system, etc.) but renal involvement (often in the form of rapidly progressive glomerulonephritis [RPGN]) seems to be one of the most clinically significant and perhaps the most severe [48,78]. The frequency of occurrence of renal involvement is greater in GPA (80%) and MPA (90%) and lesser in EGPA (45%) [48]. Clinical features of renal involvement include hematuria with dysmorphic red blood cells and red cell casts, proteinuria and renal failure [48,78]. RPGN in AAV can quickly result in end-stage renal disease (ESRD) if not urgently and aggressively addressed.

Renal biopsy remains the gold standard for the diagnosis of AAV [5].

Disease activity in AAV is assessed using the Birmingham Vasculitis Activity Score (BVAS) [104], while damage in AAV (which can be either disease or treatment-related) can be assessed using the Vasculitis Damage Index (VDI) [96]. The remainder of this article shall focus on the different treatment methods for renal AAV and also the prognostic determinants of renal and patient survival.

TREATMENT OF AAV

Treatment goals in AAV include achievement of good disease control in order to prevent further organ damage, prevention of relapse and management of treatment toxicity [6,81]. Some steps that can be taken in the management of treatment toxicity are listed in table 1. In order to optimize the treatment of AAV, the European Vasculitis Society (EUVAS) has categorized the disease stages into 5 categories as follows [77]:

- **Localized disease:** Defined as the presence of upper and/or lower airway disease in the absence of other systemic involvement or constitutional symptoms.
- **Early systemic disease:** Defined as the presence of any disease which is not organ- or life-threatening.
- **Generalized disease:** Defined as the presence of renal or other organ-threatening disease and a serum creatinine level of below 500 µmol/l (5.6 mg/dl).
- **Severe disease:** Defined as the presence of renal or other vital organ failure and a serum creatinine level of above 500 µmol/l (5.6 mg/dl).
- **Refractory disease:** Defined as the presence of progressive disease that is unresponsive to standard therapy (e.g. glucocorticoids and cyclophosphamide).

Treatment of AAV is made up of two phases, namely induction of remission and maintenance of remission (see figure 1). The choice of treatment regimen in each phase is based on the disease stage and severity [95].

Table 1. Adjunctive (supportive) therapy in ANCA-associated vasculitides

1. Mesna and adequate fluid intake (or infusion) with CY.
2. Antiemetics with IV-CY.
3. TMP-SMX* as standard prophylaxis against <i>Pneumocystis jirovecii</i> and <i>Legionella</i> infections in patients on immunosuppressive therapy (avoid concomitant use of TMP-SMX with MTX as much as possible).
4. Mupirocin for elimination of nasal carriage of <i>Staphylococcus aureus</i> .
5. Pneumococcal and flu vaccination for patients on immunosuppressive therapy.
6. Osteoporosis prophylaxis for patients on high-dose glucocorticoids.
7. BP control with dietary Na ⁺ restriction and antihypertensive drugs.
8. Hormonal augmentation (e.g. use of leuprolide in women and testosterone in men) to preserve fertility in patients taking CY; sperm and oocyte cryopreservation may also be considered.
9. TB screening for patients on immunosuppressive therapy.
10. Antifungal prophylaxis for patients on immunosuppressive therapy.
11. Gynecological screening against CIN in female patients on immunosuppressive therapy.
12. Folic or folinic acid supplementation for patients on MTX.
13. Use of thromboembolic prophylaxis where necessary.

*TMP-SMX is also useful for elimination of chronic nasal carriage of *Staphylococcus aureus* which is a recognized risk factor for relapsing disease in GPA. **Abbreviations:** BP - blood pressure; CIN - cervical intraepithelial neoplasia; CY - cyclophosphamide; GPA - granulomatosis with polyangiitis; IV - intravenous; Mesna - 2-mercaptoethane sulfonate sodium; MTX - methotrexate; TB - tuberculosis; TMP-SMX - trimethoprim –sulfamethoxazole

INDUCTION THERAPY

This involves the use of treatment regimens for a period of 3-6 months to induce remission [95]. The treatment methods used in this phase are as follows:

1. High-dose glucocorticoids: Glucocorticoids are an integral part of the treatment regimen for AAV. For induction therapy in renal disease, high-dose glucocorticoids are used in combination with another immunosuppressive drug (e.g. cyclophosphamide or rituximab) [78,81]. One study however linked the extended use of glucocorticoids (>6 months) with an increased risk of infection without a significant decrease in the risk of disease relapse [68]. Apart from increased susceptibility to infections, other potential adverse effects of high-dose and/or long-term glucocorticoid use include osteoporosis, cushingoid features, weight gain, diabetes mellitus, cataracts, gastrointestinal complications, increased risk of adverse cardiovascular events (e.g. ischemic heart disease, heart failure), nonmelanoma skin cancers, and others [54,92]. Measures aimed at limiting the adverse effects of glucocorticoids include the use of the lowest dose of glucocorticoids for

the shortest period of time required to achieve treatment objectives, treatment of preexisting comorbidities (e.g. hypertension, osteoporosis, diabetes mellitus) that may increase risk when glucocorticoid administration is required (see table 1), and monitoring of those undergoing glucocorticoid treatment for adverse effects that may be ameliorated by the use of additional interventions [92]. The ongoing PEXIVAS (*Plasma exchange and glucocorticoid dosing in the treatment of anti-neutrophil cytoplasm antibody-associated vasculitis*) trial seeks to provide more information on the optimal dosing of glucocorticoids in AAV so as to improve treatment efficacy and reduce toxicity [116].

2. Cyclophosphamide-based therapy: The most commonly used induction therapy in renal AAV is the combination of cyclophosphamide (CY) and glucocorticoids [48,95]. This classical combination has been very instrumental in altering the natural history of AAV [48]. Oral CY has most often been used, but the CYCLOPS (Daily oral versus pulse cyclophosphamide for renal vasculitis) trial has shown that intravenous pulse CY (IV-CY) is equally as efficacious as the oral form of the drug for induction of remission. IV-CY also has an added advantage of guaranteeing a lower cumulative dose of CY, thereby reducing the risks of adverse effects (e.g. bone marrow suppression, increased susceptibility to infections, bladder toxicity, infertility, cardiovascular diseases and malignancies) commonly associated with this cytotoxic agent [18,28,77,81]. The only drawback of IV-CY is that it has been associated with a greater risk of relapse than daily oral CY [37]. In using IV-CY, there is a need for dose adjustment in patients over 60 years old and in those with impaired renal function [18]. CY-based therapy is currently recommended as the standard therapy for remission induction in generalized disease and also in severe AAV (in combination with plasma exchange) [77,95].

3. Rituximab-based therapy: Rituximab (RTX) is a chimeric monoclonal antibody directed against CD20. Its role is to deplete B cells, which are believed to play a role in the pathogenesis of AAV [95]. A number of studies have been conducted to investigate the efficacy of RTX in the treatment of AAV. The RAVE (Rituximab in ANCA-associated vasculitis) and RITUXVAS (Rituximab versus cyclophosphamide in ANCA-associated renal vasculitis) trials and their long-term follow-up demonstrated that RTX-based therapy (RTX and glucocorticoids) was as efficacious as CY-based therapy for remission induction in patients with severe AAV, with their safety profiles being identical [50,51,100,103]. A recently published post hoc analysis of patients from the RAVE trial who had renal involvement also showed that RTX-based therapy was as effective as CY-based therapy in inducing remission in these patients [31]. Another advantage of RTX is that this drug, unlike CY, has not been linked to infertility, thereby making it safer for use by patients of reproductive age. RTX can therefore serve as a therapeutic alternative to CY for patients with renal AAV, particularly in those desiring to avoid some of the adverse effects associated with the use of the latter.



Interestingly, a number of recently published studies have also shown that the use of a combination regimen of RTX and CY was more effective in inducing a prolonged disease-free remission than an RTX-only regimen. For instance, in a study by Mansfield et al. involving patients with renal AAV, RTX-based low-dose CY therapy (a combination of RTX, low-dose CY and a reducing protocol of daily oral glucocorticoids) was also found to be efficacious in inducing long-term disease-free remission [64]. In another study involving a retrospective analysis of RTX-treated AAV patients, it was found that RTX-treated patients who were never exposed to CY had a shorter time to relapse (50% by 8 months) in comparison to RTX-treated patients with a history of prior or concurrent exposure to CY (50% by 24 and 30 months respectively) [69]. Some of the reported adverse effects associated with RTX use include infusion reactions, hypogammaglobulinemia, blunted humoral response to immunization and reactivation of latent hepatitis B virus [43,59,65,81]. There have also been some reported cases of progressive multifocal leukoencephalopathy (PML) occurring in patients treated with RTX [15,75]. In most of these cases, the patients were also treated with several other immunosuppressive agents, thereby making it difficult to solely attribute the development of PML to RTX use. However, there is a need to inform patients of the existence of such potential risk. There is also a need for continued monitoring and assessment of patients treated with this agent. Infusion reactions occur in about 20% of patients and may be minimized by appropriate premedication. RTX-induced hypogammaglobulinemia occurs in a minority of patients, and this has been associated with prior exposure to other immunosuppressives such as CY and glucocorticoids [65]. However, only patients with recurrent infections due to severe RTX-induced hypogammaglobulinemia are treated with intravenous immunoglobulin replacement [34]. Patients treated with RTX have also been shown to have an impaired humoral response to most vaccines [43]. It is therefore advisable that patients be vaccinated at least 2 weeks before RTX administration, or 4 months after RTX [43, 81].

4. Mycophenolate mofetil (MMF): In a number of small, prospective, open-label trials involving MPA patients with mild to moderate renal involvement, in which the efficacies of MMF and CY for remission induction were compared, MMF was found to be effective in ameliorating the symptoms of renal disease, thereby indicating that MMF may represent an alternative to CY therapy in these patients [36,42,97]. One retrospective study in AAV patients with moderate renal failure also showed that MMF had a similar efficacy profile as CY [21]. However, preliminary results from the MYCYC (Mycophenolate mofetil versus cyclophosphamide for remission induction in ANCA associated vasculitis) trial failed to demonstrate the noninferiority of MMF to IV-CY for remission induction at the primary end point (6 months) in patients with newly diagnosed AAV [49]. Thus, recommendations on the use of MMF for induction must await the publication of the final results and long-term follow-up of this trial.

5. Plasma exchange: Plasma exchange (PLEX) or plasmapheresis is presently indicated as an adjunct to standard therapy (e.g. CY and glucocorticoids) for the treatment of two manifestations of severe AAV, namely severe renal disease and diffuse alveolar hemorrhage [29,48,77,119]. With PLEX, autoantibodies such as ANCA (which are believed to play a role in the pathogenesis of AAV) can be removed from the circulation. Results from the MEPEX (Methylprednisolone or plasma exchange for severe renal vasculitis) trial comparing the use of PLEX to intravenous pulse methylprednisolone indicate that PLEX was associated with a speedier recovery from AAV-induced renal failure and also a decreased risk of progression to ESRD [45]. The MEPEX long-term follow-up however failed to demonstrate a clear clinical benefit of PLEX over intravenous pulse methylprednisolone [114]. PLEX has also been shown to be efficacious in PR3-ANCA patients with moderate renal failure when used in combination with standard induction therapy [33]. However, evidence regarding PLEX is still debated and is presently being addressed through a randomized trial called PEXIVAS (Plasma exchange and glucocorticoid dosing in the treatment of anti-neutrophil cytoplasm antibody-associated vasculitis) [116].

MAINTENANCE THERAPY

It is recommended that after the induction of remission, maintenance therapy be continued for at least 18-24 months, as early withdrawal of therapy is associated with a greater risk of disease relapse [19,77,81]. Treatment regimens used for remission maintenance are as follows:

Azathioprine: Azathioprine is presently recommended as the standard therapy for maintenance of remission in AAV [81]. The CYCAZAREM (Cyclophosphamide versus azathioprine for the maintenance of remission) trial in patients with generalized AAV has shown that the replacement of CY with azathioprine after a successful induction of remission with the former did not result in an increase in the relapse rate; this substitution helped prevent prolonged exposure to CY [46]. Azathioprine is a prodrug that is metabolized to 6-mercaptopurine (6-MP), which is then further metabolized to several metabolites including 6-thioguanine (6-TG) and 6-methylmercaptopurine (6-MMP). Two enzymes are responsible for catalyzing these reactions: thiopurine methyltransferase (TPMT) and hypoxanthine phosphoribosyltransferase. Bone marrow suppression correlates with elevated levels of 6-TG greater than 400, while elevated levels of 6-MMP greater than 5700 correlate with liver toxicity, manifested as increased liver enzymes. Hence, it is suggested that both TPMT genotype and TPMT enzyme activity (phenotype) be assessed in all patients in whom azathioprine is considered. Monitoring of the complete blood count and liver function tests weekly for the first month and then monthly must be continued as long as the patient is being given azathioprine.

Methotrexate: The WEGENT trial and its long-term follow-up comparing methotrexate (MTX) with azathio-

prine as maintenance therapy in AAV showed that MTX had a similar efficacy and safety profile as azathioprine [82,86]. Results from the NORAM (Non-renal Wegener's granulomatosis treated alternatively with methotrexate) trial showed that MTX was less effective as maintenance therapy in patients who did not receive CY for induction therapy [19]. MTX can be used as alternative therapy for remission maintenance in patients with mild renal disease (serum creatinine level <130 µmol/l [1.5 mg/dL] or estimated glomerular filtration rate (eGFR) > 30- 40 mL/min/1.73 m²) who cannot tolerate azathioprine [25,77,95]. Also the use of MTX for maintenance treatment requires continuation of therapy for a period longer than 12 months; this is because earlier cessation of therapy is a risk factor for relapse [19].

Mycophenolate mofetil: MMF was found to be less efficacious than azathioprine for remission maintenance in the IMPROVE (International mycophenolate mofetil protocol to reduce outbreaks of vasculitides) trial due to a higher frequency of disease relapse associated with its use. The two agents were however similar in terms of adverse events [40]. In other studies, MMF was found to be effective for remission maintenance in patients with renal AAV [21,80,97]. MMF is presently recommended for use as maintenance therapy in those patients who can neither tolerate azathioprine nor use MTX because of impaired renal function [25,81].

Rituximab: The use of RTX as maintenance therapy is still evolving. An 18-month follow-up to the RAVE trial, already alluded to in the section on induction therapy, showed that a single course of RTX (once weekly administration for a total of 4 weeks) during induction therapy, followed by placebo for maintenance therapy, was as efficacious as continuous administration of conventional immunosuppressive agents (CY for induction therapy followed by azathioprine for maintenance therapy) over the 18-month period in patients with severe AAV [100]. A recently published study by the French Vasculitis Study Group demonstrated that the use of RTX as maintenance therapy (after an initial RTX-based induction therapy) in patients with GPA was associated with reduced relapse rates [13]. Most of the other studies currently available in this area are retrospective studies on the use of RTX as preemptive maintenance therapy in patients with relapsing or refractory AAV, and the results have been quite promising [16,55,90,99]. Results from the MAINRITSAN (Maintenance of remission using rituximab in systemic ANCA-associated vasculitis) trial and its extended follow-up study comparing the efficacy of RTX to azathioprine for remission maintenance have shown RTX to be associated with a lower relapse risk and also better overall survival compared to azathioprine [35,106]. Final results from the ongoing MAINRITSAN 2 (Maintenance of remission using rituximab in systemic ANCA-associated vasculitis II) and RITAZAREM (Rituximab vasculitis maintenance study) trials will help provide more information on the efficacy of RTX as maintenance therapy [111,112]. The main objective of MAINRITSAN 2 is to ascertain whether

RTX administration based on ANCA progression or CD19+ lymphocyte count is as effective as fixed periodic administration of the same agent [111]. RITAZAREM is aimed at testing the efficacy of repeated periodic administration of RTX in relapse prevention in AAV and also at comparing the efficacy of RTX to that of older maintenance treatments such as azathioprine and MTX [112].

Low-dose glucocorticoids: It is recommended that low-dose glucocorticoids be used in combination with other immunosuppressive agents (steroid-sparing drugs) such as azathioprine, MTX, MMF or RTX for remission maintenance. Steroid-sparing drugs have a two-fold benefit, namely to reduce or eliminate the need for glucocorticoids while also maintaining good disease control. Upon achieving sustained remission, the glucocorticoid dose can then be gradually tapered off [25,77,81].

Leflunomide: The LEM (Leflunomide versus methotrexate in the therapy of ANCA vasculitis) trial, which involved patients with generalized GPA and a serum creatinine level of < 115 µmol/l (1.3 mg/dl) and which compared leflunomide with MTX for remission maintenance, was terminated prematurely due to a higher than expected incidence of relapse occurring in the MTX arm of the trial. However, available results from this trial showed that leflunomide was more efficacious than MTX in preventing disease relapse, with its only drawback being increased incidence of adverse effects [71]. Therefore, the role of leflunomide in the treatment of AAV patients with significant renal manifestations remains to be established.

END-STAGE RENAL DISEASE (ESRD) IN AAV

Statistics on the incidence of ESRD in AAV patients vary based on different patient cohort series; in one study, ESRD was shown to occur in about 26% of AAV patients [61]. ESRD may be due to acute kidney injury or progressive chronic kidney disease [61,78] and is associated with a considerable degree of morbidity and mortality in these patients. Risk factors for progression to ESRD include a higher serum creatinine level at presentation, CY-resistant disease and global glomerulosclerosis on renal biopsy [6,61].

IMMUNOSUPPRESSIVE TREATMENT IN ESRD AAV PATIENTS ON MAINTENANCE DIALYSIS

Results from different cohort series showed that of those patients requiring dialysis during the acute phase of disease, more than half went on to recover sufficient renal function allowing them to be weaned off dialysis [26]. These results therefore support the use of immunosuppressive therapy in ESRD AAV patients needing dialysis. However, studies also showed that AAV patients on chronic dialysis had a lower rate of relapse [39,61]. Furthermore, an increased incidence of infection was found to occur in AAV patients who were on chronic dialysis and were being concurrently treated with maintenance immunosuppressive agents, thereby suggesting that such



patients might benefit from maintenance immunosuppressive therapy of limited duration [39,61]. Presently there is no evidence from randomized control trials indicating the optimal duration of immunosuppressive treatment in ESRD AAV patients. The only available evidence concerning the treatment of this patient group is based on expert opinion [26], and it is as follows:

- For patients without evidence of active renal (absence of hematuria with dysmorphic red blood cells) and extrarenal manifestations of disease, immunosuppressive treatment should be continued until the patient has completed 3-6 months of maintenance therapy, after which the patient can then be weaned off immunosuppressive agents provided the disease remains inactive.
- Patients with persistent active renal disease (i.e. persistence of active urinary sediments) but no evidence of extrarenal disease are treated with immunosuppressive agents as in patients without ESRD. This is because continued immunosuppressive therapy in such patients might result in recovery of sufficient renal function, allowing them to be weaned off dialysis.
- other maintenance dialysis patients with active AAV are treated in a manner similar to patients not requiring maintenance dialysis, with the type and duration of immunosuppressive therapy being dependent on patient response and on the presence or absence of relapsing disease.
- the use of MTX for maintenance immunosuppression is contraindicated in patients on chronic dialysis and also in those with moderate to severe renal failure. CY also requires dose modification in ESRD patients due to the risk of myelosuppression.

KIDNEY TRANSPLANTATION

Kidney transplantation is an excellent treatment option for patients with ESRD resulting from AAV [76]. The risk of disease recurrence in patients receiving a kidney transplant is low, and this is likely due to the excellent effects of the modern day antirejection regimen in lowering the incidence of relapse in these patients [26,76]. MPA patients with ESRD have been found to have worse renal allograft and patient survival than non-AAV patients with ESRD [4]. ANCA positivity at the time of transplantation does not increase the risk of disease relapse after transplantation [56], and therefore should not preclude kidney transplantation provided the patient is in clinical remission [76]. It is currently recommended that AAV patients be in clinical remission for at least 12 months before undergoing transplantation [4,56]. Relapse involving the transplanted kidney is treated in a manner similar to that occurring in the native kidneys [88].

RELAPSING DISEASE

Despite implementation of effective treatment plans, some AAV patients will experience disease relapse (flare). The risk factors for relapse are listed in table 2. Clinical featu-

res of relapsing disease include rapidly increasing serum creatinine coupled with the presence of an active urinary sediment and/or recurrence or exacerbation of proteinuria, the presence of active necrosis or crescent formation on renal biopsy, or features of active vasculitis in other organ systems such as the lungs, gastrointestinal tract, eye, etc. [30,79].

To date, no reliable biomarkers have been established as being capable of predicting disease relapse. Several studies have assessed the usefulness of ANCA titers in predicting relapse among AAV patients; however, serial ANCA titers or changing levels of anti-PR3 antibodies were not found to be reliable predictors of relapsing disease in most of these studies [48,73,107]. A recent meta-analysis of such trials showed a link between a rise or persistent elevation in ANCA and relapse [109]. However, the authors of this meta-analysis acknowledged that their results showed only a modest correlation. Another recently published study by Hogan et al. in GPA patients showed that relapses could be predicted in 59% of patients when a combined rise in anti-PR3 antibody, C-reactive protein (CRP) and neutrophil count was observed in the 6-month period prior to a relapse event [41]. As a result, making therapeutic decisions based on ANCA titer alone is not encouraged [107].

Research indices of disease relapse include serum proteins/factors such as calprotectin (S100A8/A9), CC chemokine ligand 18 (CCL18), CD5+ regulatory B cells and urinary proteins such as alpha-1 acid glycoprotein (AGP), kidney injury molecule-1 (KIM-1), neutrophil gelatinase-associated lipocalin (NGAL) and monocyte chemoattractant protein-1 (MCP-1). Recent studies involving patients from the RAVE trial have shown that PR3-ANCA-associated vasculitis patients who fail to decrease serum calprotectin levels from baseline values while on treatment are at an increased risk of early relapse [83]. CCL18 are chemokines produced by macrophages and dendritic cells in the kidney and whose levels have been shown to increase during renal relapse and decrease after the reintroduction or intensification of immunosuppressive therapy [10]. A study by Bunch et al. showed that a low percentage of CD5+ regulatory B cells at B cell repopulation predicts a shorter time to relapse following treatment with RTX irrespective of the treatment dose [12]. Increased levels of urinary proteins AGP, KIM-1, NGAL and MCP-1 have also been demonstrated during renal relapse [60]. Of these urinary proteins, MCP-1 demonstrated a greater capability of distinguishing between active renal disease and remission in AAV.

Distinguishing between systemic infection and active AAV/disease flare: In the management of relapsing AAV, one challenge that the clinician faces is that of distinguishing between infection and active vasculitis. This situation is further compounded by the fact that infections are also known to precipitate relapse in AAV patients [81]. In a paper by Buhaescu et al. analyzing the usefulness of procalcitonin (PCT) levels in detecting systemic infection concomitant with systemic autoimmune disorders, PCT was shown to possess a diagnostic sensitivity of 53-100% and a

Table 2. Factors associated with increased risk for relapsing and refractory (treatment-resistant) ANCA-associated vasculitides

A.) RELAPSING DISEASE:	B.) REFRACTORY (TREATMENT-RESISTANT) DISEASE
PR3-ANCA	Female gender (associated with ↑ resistance to initial therapy)
ANCA positivity in EGPA	African/ African American ethnicity (associated with ↑ resistance to initial therapy)
Lung or ENT involvement	Advanced age
GPA	Severe renal disease at presentation
Cardiovascular involvement	Lack of optimization of dosage of immunosuppressive therapy
Lower SCr (< 200µmol/l [2.2 mg/dl]) at diagnosis	Poor drug compliance
History of relapsing disease	
Reduced cumulative exposure to CY (as occurs with IV- CY use)	
Early withdrawal of immunosuppressive treatment	
S. aureus infection in GPA	
High VDI score	
Rising or persistently elevated ANCA titer	
Reduced eosinophil count at diagnosis (EGPA)	
Poor drug compliance	

Abbreviations: ANCA - antineutrophil cytoplasmic antibody; CY - cyclophosphamide; EGPA - eosinophilic granulomatosis with polyangiitis; ENT - ear, nose and throat; GPA - granulomatosis with polyangiitis; IV - intravenous; PR3 - proteinase 3; SCr - serum creatinine; S. aureus - *Staphylococcus aureus*; VDI - vasculitis damage index.

specificity of 84-97% (depending on the selection criteria) and was also found to be superior to other inflammatory markers tested (e.g. CRP and leukocyte count) [11]. This could be attributed to the findings that PCT levels (unlike other inflammatory markers) were not significantly altered by impaired renal function, hemodialysis, autoimmune diseases or treatment with immunosuppressive agents [11,98]. However, it must be noted that although elevated PCT levels were commonly found in infections, they could also be present in some AAV patients with high disease activity scores in the absence of systemic infection [11,57]. Therefore measurement of PCT levels should not replace structured patient evaluation, which should include a complete history and physical examination coupled with relevant immunological, microbiological, radiological and histopathological investigations [11]. When all efforts have been made, and it still remains impossible to distinguish between infection and active vasculitis, then both should be treated simultaneously [24]. For the simultaneous treatment of infection and AAV, intravenous immunoglobulin (IVIG) infusion may be considered as a treatment option.

Treatment of relapsing disease: Several options are available depending on the relapse timing (whether occurring during maintenance therapy or after its cessation) and severity (disease manifestations), and on the presence of prior history of relapsing disease [24]. When there are doubts as to the presence of a relapse or as to the severity of the relapse, it might be necessary to obtain a tissue biopsy [24,43]. Treatment options for relapsing disease are as follows:

- Patients with a minor relapse (mild, non-organ-threatening disease such as recurrent dysmorphic hematuria in

the absence of a rise in the serum creatinine level) who are still on maintenance therapy at the time of relapse can be treated by increasing the dose of glucocorticoids and of the concurrent maintenance immunosuppression [24,81].

- Patients who experience a minor relapse (mild, non-organ-threatening disease) after the cessation of maintenance therapy can be treated by a reintroduction of the prior maintenance immunosuppression along with a short course (< 1 month) of glucocorticoids. In this situation, the maintenance therapy should be administered for a longer period than was used prior to the relapse [24].
- For patients with a major (severe) relapse (e.g. those with a rapidly rising serum creatinine level), treatment often requires a repeat of the initial induction therapy (e.g. CY) or a conversion to RTX [24,95]. The RAVE trial showed RTX to be more efficacious than CY in the treatment of relapsing disease [103]. Therefore, for this reason and also to avoid the possible adverse effects that could result from repeated exposure to CY, RTX-based therapy might be the preferred regimen in these patients [24,43]. Re-treatment with RTX is also recommended for those who relapse following a prior successful induction with RTX [34,72]. Patients with multiple relapses (i.e. more than one episode of relapse) are also treated with RTX to avoid repeated exposure to CY [24]. Addition of PLEX to the immunosuppressive treatment protocol may also be considered in patients with a major relapse [81]. For patients with a major relapse who are unable to tolerate CY or RTX, MMF can be tried [24,101].



REFRACTORY (TREATMENT-RESISTANT OR PERSISTENT) DISEASE

Refractory disease has been defined in a previous section. Its frequency is estimated at 20% [1]. Renal manifestations of refractory AAV include a progressive deterioration in renal function coupled with the persistence of an active urinary sediment [79]. The risk factors for refractory AAV are listed in table 2. It is recommended that refractory disease be treated in close collaboration with expert centers [77,81]. The various treatment options include:

- **Rituximab:** It is presently the first-line agent for treatment-resistant disease. A number of retrospective trials have shown RTX to be quite effective in the treatment of refractory AAV, with a high frequency of remission among patients [63,87,89,91,118]. However, the evidence for RTX efficacy in EGPA is still relatively weak, although it may work in certain settings. There are few studies available in this area, and most have involved very few patients or are case reports [84,89,91]. This is due to the fact EGPA patients have been excluded from most RTX trials. In other recently published retrospective studies, RTX was shown to be efficacious in the treatment of patients with refractory EGPA [74,108].
- **Mycophenolate mofetil:** In one study, MMF was found to be useful in the treatment of CY-resistant AAV [52].
- **Gusperimus (15-deoxyspergualin [DSG]):** Gusperimus is an analogue of spergualin with immunomodulatory actions towards T cells, B cells, macrophages, dendritic cells, antigen-presenting cells and neutrophils [85]. Trials have demonstrated the effectiveness of this agent in the treatment of refractory GPA [7,27]. Careful leukocyte control is however required with the use of this drug [7].
- **Alemtuzumab (CAMPATH-1H):** This humanized anti-CD52 monoclonal antibody has been shown to be effective in inducing remission in patients with relapsing or refractory AAV [115]. However, the use of this agent has also been associated with an increased frequency of occurrence of relapsing disease and severe adverse events [115]. Therefore, further randomized control trials are needed in order to verify the efficacy and safety of this agent.
- **Plasma exchange:** Results from a recently published study in patients who had progressive AAV despite the use of standard induction treatment showed that the addition of PLEX to standard induction therapy resulted in improved renal function in these patients [20].
- **Intravenous immunoglobulin (IVIG):** Administration of IVIG has been shown to be effective in reducing disease activity in patients with persistent disease [44]. However, since the effects of this agent do not last beyond 3 months, repeated infusion might be necessary.

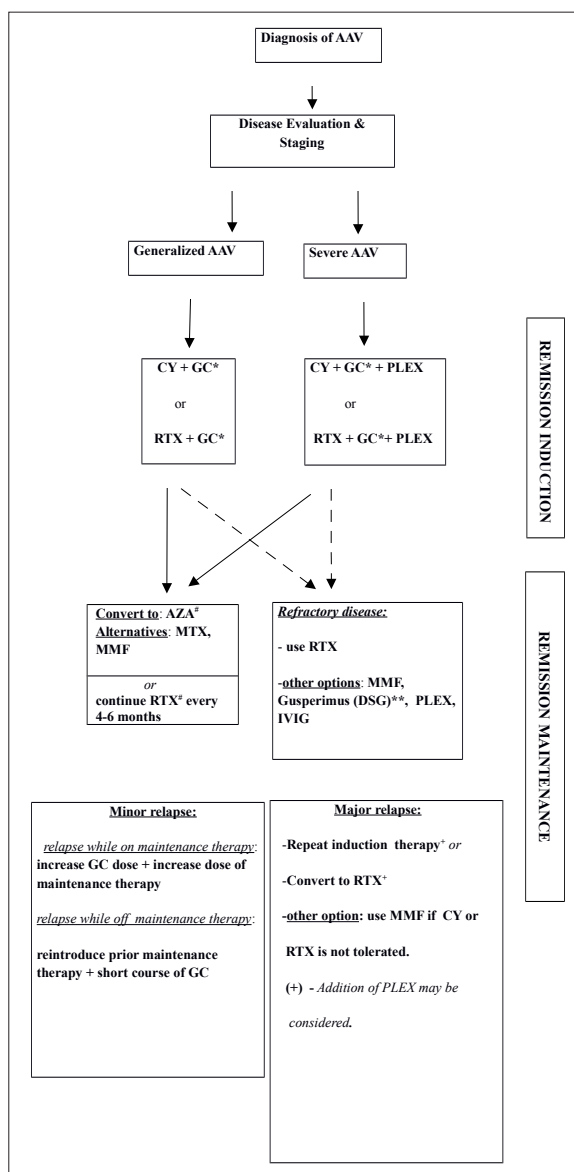


Fig. 1. Treatment algorithm for renal ANCA-associated vasculitides (modified from Schönemärck et al. [95]). * Use TMP-SMX for *Pneumocystis jirovecii* prophylaxis in those on CY or GC therapy; # - Taper GC; ** - for use in GPA. Abbreviations: AAV - ANCA-associated vasculitis; AZA - azathioprine; CY - cyclophosphamide; DSG - 15-deoxyspergualin; IV-CY - intravenous pulse cyclophosphamide; IVIG - intravenous immunoglobulin; GC - glucocorticoid; GPA - granulomatosis with polyangiitis; MMF - mycophenolate mofetil; MTX - methotrexate; PLEX - plasma exchange; RTX - rituximab; TMP-SMX - trimethoprim-sulfamethoxazole.

- **Stem cell transplantation:** Results from a few case series indicate that autologous peripheral stem cell transplantation may be a useful treatment option in patients with treatment-resistant AAV [58,102]. More studies are however required to verify the efficacy of this treatment method.

TREATMENT OF RENAL AAV IN THE ELDERLY

AAV in the elderly represents a serious condition associated with increased morbidity and mortality, especially in the first year of diagnosis [38,117]. Older patients more commonly present with MPO-ANCA-positive disease and severe renal involvement in comparison with younger patients [8,38]. Advanced age and a high serum creatinine level at presentation have been associated with a worse outcome [38,62,117]. Furthermore, older patients sometimes die from complications of therapy (e.g. infections) rather than from the underlying disease itself. These and other factors such as frailty of this age group and the presence of comorbidities all combine to hinder therapy.

Older patients are particularly sensitive to the adverse effects of immunosuppressive agents. For instance, high-dose glucocorticoids are often poorly tolerated in the elderly (due to complications such as hyperglycemia and infections), and hence there might be a need to consider dose reduction or shortening of the exposure time. CY also needs to be dose-adjusted for age and GFR in older patients in order to limit toxicity [18]. RTX may offer some advantages, but we still have limited data in this older population.

Despite a high incidence of AAV among the elderly, many randomized studies have excluded patients ≥ 75 years old. At present, there are only a few observational studies available from which to glean insight into the treatment of patients in this age category. One example is the recently published study by Weiner *et al.* involving patients aged ≥ 75 years (the largest retrospective study so far for patients of this age group). In this study, it was found that patients treated with adequate doses of CY or RTX following diagnosis had better overall survival than those who received a less aggressive therapy (i.e. those with a more frail phenotype) [117]. This study went further to show that, of the patients who were dialysis dependent at diagnosis, those treated with PLEX demonstrated better renal survival. In another study involving patients aged >80 years with renal AAV, it was found that the incidence of ESRD in the first year of diagnosis was much lower in patients treated with immunosuppressive therapy compared with their untreated counterparts [8]. In a third study that included patients with renal AAV >65 years old, treatment with standard immunosuppressive agents (CY plus glucocorticoids) was found to be both safe and efficacious in elderly patients after adjusting the CY dose for age [38]. All these studies indicate that standard immunosuppressive therapy is beneficial in elderly patients with AAV. Prophylactic medications (such as trimethoprim-sulfamethoxazole, vitamin D, bisphosphonates, antacid therapies, aspirin and statins) should also be used in older patients. Finally, more studies aimed at finding efficacious yet less toxic therapies are needed in these patients.

QUALITY OF LIFE IN AAV PATIENTS

Studies have shown that AAV patients experienced quality of life (QOL) impairment to a magnitude greater than that of the general population but comparable to that experien-

Table 3. Factors associated with decreased renal and patient survival in ANCA-associated vasculitides

1. Presence of renal involvement at diagnosis.
2. The need for renal replacement therapy at diagnosis.
3. Advanced age.
4. Black ethnicity.
5. Presence of pulmonary hemorrhage.
6. MPO-ANCA positivity.
7. Low eGFR at 6 months of immunosuppressive therapy.
8. Presence of arterial sclerosis, global glomerulosclerosis, tubulointerstitial fibrosis or atrophy on renal biopsy.
9. Presence of life-threatening complications with high SAPS II and BVAS scores.
10. Presence of renal relapse.
11. Lack of response to initial therapy
12. Presence of early organ damage.
13. Double positive disease (presence of both ANCA and anti-GBM antibody in patients with crescentic GN).
14. Reduced hemoglobin concentration.
15. Increased leukocyte count.

Abbreviations: ANCA - antineutrophil cytoplasmic antibody; BVAS - Birmingham vasculitis activity score; eGFR - estimated glomerular filtration rate; GBM - glomerular basement membrane; GN - glomerulonephritis; MPO-ANCA - myeloperoxidase-antineutrophil cytoplasmic antibody; SAPS II - simplified acute physiology score II

ced by patients with other chronic diseases [3]. Patient with relapsing AAV reported a much worse QOL than those without relapsing disease [14]. One of the key contributors to QOL impairment in AAV is fatigue [3]. Fatigue was found to be strongly associated with the following factors: sleep disturbance, presence of pain, dysfunctional coping behaviors (i.e. denial and behavioral disengagement), presence of inflammation (as indicated by an elevated CRP level) and female gender [2]. Medication-related support from physicians and partners was found to be a predictor of improved health-related QOL in these patients [14]. The British Society for Rheumatology (BSR) and British Health Professionals in Rheumatology (BHPR) guidelines for the management of adults with AAV recommend a regular assessment of QOL using tools such as the 36-item Short Form (SF-36) [81]. SF-36, an easy-to-use quality of life measure, can be freely accessed online [70].

PROGNOSIS AND OUTCOME IN AAV PATIENTS

Treatment greatly modifies the natural history of AAV, as 1-year mortality in untreated systemic disease can be as high as 80% [78]. Because renal involvement is often a part of the AAV spectrum, it is a strong determinant of final outcome [29]. The 5-year renal and patient survival with adequate treatment ranges from 65 to 75% [62]. The



factors associated with reduced renal and patient survival in AAV are listed in table 3.

POTENTIAL THERAPIES FOR AAV

Potential therapies for AAV include:

- **Ofatumumab:** This is a humanized anti-CD20 monoclonal antibody which, like RTX, acts by depleting B cells. One retrospective study showed ofatumumab to be effective in the treatment of AAV patients including those with renal disease, thereby making this agent a potential alternative for use in patients who cannot take or tolerate RTX [66]. Also, the cost per course of ofatumumab is lower compared to RTX (£2548 versus £3492 in the United Kingdom) [66]. Prospective studies are needed to further verify the efficacy of this agent.
- **Belimumab:** Belimumab is a monoclonal antibody directed against B-cell activating factor belonging to the tumor necrosis family (BAFF), also called B-lymphocyte stimulator (BLyS). This agent is presently undergoing phase 3 evaluation to ascertain its efficacy in combination with azathioprine for remission maintenance in AAV patients (the BREVAS [Belimumab in remission of vasculitis] trial) [110].
- **CCX168 (antagonist of human C5a receptor):** This agent was found to be effective in ameliorating anti-MPO-induced necrotizing glomerulonephritis when administered orally to mice expressing human C5a receptor (CD88) [120]. CCX168 is presently being evaluated in renal AAV patients, and recently published results from the phase 2 trials have shown that the agent is both safe and efficacious in inducing renal remission in these patients [17].
- **Antithymocyte globulin (ATG):** Although this agent was shown to possess some efficacy against severe refractory GPA in a single study using a protocol designed by EUVAS [94], its role in the treatment of renal manifestations of AAV is still to be determined. Also, ATG should only be used under special caution after exclusion of concomitant infection and fluid overload [94]. Routine usage is not recommended.
- **Bortezomib (BTZ):** In experimental animal (mice) models, BTZ (a proteasome inhibitor) was found to be more efficacious than a steroid/CY combination regimen in decreasing the number of MPO-specific plasma cells, thereby reducing anti-MPO titers and preventing the development of ANCA-associate glomerulonephritis [9]. Since this is only laboratory evidence, more studies are needed to ascertain the efficacy and safety of this agent in the treatment of AAV patients. Moreover, the risk of thrombocytopenia/pancytopenia (concomitant risk of infection) cannot be neglected when BTZ is used.
- **Fostamatinib:** Fostamatinib is a selective spleen tyrosine kinase (Syk) inhibitor that blocks B cell activation. Fo-

stamatinib has been shown to be effective in the treatment of experimental autoimmune glomerulonephritis in rat models [67]. Further studies are however needed in order to ascertain the efficacy of this agent in AAV patients.

- **Gabexate mesylate:** This protease inhibitor is capable of inhibiting injury to endothelial cells and has also been shown to be useful in the treatment of disseminated intravascular coagulation (a possible complication in the course of severe AAV) in both ANCA-positive and -negative MPA patients with renal involvement, with the resultant amelioration of both the coagulation disorder and renal function [32].

FUTURE PERSPECTIVES IN THE TREATMENT OF AAV

Ongoing and future studies will be aimed at:

- Adapting the renal histopathology classification system developed by Berden et al. [5] for use in predicting renal response to treatment and also to guide future therapy in AAV patients [113]:
- Determining the optimal duration of maintenance treatment. Current guidelines recommend that after the induction of remission, maintenance treatment should be continued for about 18-24 months. However, considering that AAV is a chronic disease with a remitting and relapsing course, it might be necessary to extend the duration of maintenance therapy beyond the 24-month period. Final results of trials such as REMAIN (Randomized trial of prolonged remission-maintenance therapy in systemic vasculitis) will help inform us of the optimum duration of maintenance therapy in AAV patients [23].
- Developing novel and more effective strategies for the treatment of AAV. This could be by way of target-specific therapeutics (e.g. biologics) or through synthetic immunoglobulins. For instance, Kameoka et al. reported that synthetic human single chain Fv (hScFv) of immunoglobulin G (IgG) selected from a library of clones was effective in improving the symptoms of MPO-ANCA-related vasculitis in mice models [53].

CONCLUSION

AAV is a chronic disease with a relapsing and remitting course. Essential steps in proper disease management include rapid diagnosis and prompt and ongoing treatment with immunosuppressive therapy and other adjunctive agents in order to ensure good disease control, prevent relapses and limit drug toxicity. However, the scenario can be compounded by the occurrence of relapsing and refractory disease in patients with contraindications or intolerance to standard immunosuppressive therapy, thereby pointing to the need for the development and verification of newer treatment methods that will further help widen the therapeutic options available to these patients. This can be achieved through the design of controlled

studies aimed at establishing the efficacy and safety of potentially applicable therapeutic agents and also through further studies aimed at identifying novel therapeutic targets in AAV. There is also a need for more studies

geared towards identifying potential serum and urinary biomarkers capable of monitoring treatment response in these patients. The effects of these measures would be improved patient care and outcome.

REFERENCES

- [1] Alberici F, Jayne D.R.: Impact of rituximab trials on the treatment of ANCA-associated vasculitis. *Nephrol. Dial. Transplant.*, 2014; 29: 1151-1159
- [2] Basu N., McClean A., Harper L., Amft E.N., Dhaun N., Luqmani R.A., Little M.A., Jayne D.R., Flossmann O., McLaren J., Kumar V., Erwig L.P., Reid D.M., Jones G.T., Macfarlane G.J.: Explaining fatigue in ANCA-associated vasculitis. *Rheumatology*, 2013; 52: 1680-1685
- [3] Basu N., McClean A., Harper L., Amft E.N., Dhaun N., Luqmani R.A., Little M.A., Jayne D.R., Flossmann O., McLaren J., Kumar V., Erwig L.P., Reid D.M., Macfarlane G.J.: Jones G.T.: The characterisation and determinants of quality of life in ANCA associated vasculitis. *Ann. Rheum. Dis.*, 2014; 73: 207-211
- [4] Beck L., Bomback A.S., Choi M.J., Holzman L.B., Langford C., Mariani L.H., Somers M.J., Trachtman H., Waldman M.: KDOQI US commentary on the 2012 KDIGO clinical practice guideline for glomerulonephritis. *Am. J. Kidney Dis.*, 2013; 62: 403-441
- [5] Berden A.E., Ferrario F., Hagen E.C., Jayne D.R., Jennette J.C., Joh K., Neumann I., Noël L.H., Pusey C.D., Waldherr R., Bruijn J.A., Bajema I.M.: Histopathologic classification of ANCA-associated glomerulonephritis. *J. Am. Soc. Nephrol.*, 2010; 21: 1628-1636
- [6] Berden A., Göçeroglu A., Jayne D., Luqmani R., Rasmussen N., Bruijn J.A., Bajema I. Diagnosis and management of ANCA associated vasculitis. *BMJ*, 2012; 344: e26
- [7] Birck R., Warnatz K., Lorenz H.M., Choi M., Haubitz M., Grünke M., Peter H.H., Kalden J.R., Göbel U., Drexler J.M., Hotta O., Nowack R., Van Der Woude F.J.: 15-Deoxyspergualin in patients with refractory ANCA-associated systemic vasculitis: a six-month open-label trial to evaluate safety and efficacy. *J. Am. Soc. Nephrol.*, 2003; 14: 440-447
- [8] Bomback A.S., Appel G.B., Radhakrishnan J., Shirazian S., Herlitz L.C., Stokes B., D'Agati V.D., Markowitz G.S.: ANCA-associated glomerulonephritis in the very elderly. *Kidney Int.*, 2011; 79: 757-764
- [9] Bontscho J., Schreiber A., Manz R.A., Schneider W., Luft F.C., Ketzritz R.: Myeloperoxidase-specific plasma cell depletion by bortezomib protects from antineutrophil cytoplasmic autoantibodies-induced glomerulonephritis. *J. Am. Soc. Nephrol.*, 2011; 22: 336-348
- [10] Brix S.R., Krebs C., Noriega M., Janneck M., Iking-Konert C., Wiech T., Panzer U., Stahl R.A.: CCL 18 in relapsing ANCA-associated necrotizing glomerulonephritis. *Nephron*, 2015; 129: 112-113 (17th International Vasculitis & ANCA Workshop)
- [11] Buhaescu I., Yood R.A., Izzedine H.: Serum procalcitonin in systemic autoimmune diseases - where are we now? *Semin. Arthritis Rheum.*, 2010; 40: 176-183
- [12] Bunch D.O., Mendoza C.E., Aybar L.T., Kotzen E.S., Colby K.R., Hu Y., Hogan S.L., Poulton C.J., Schmitz J.L., Falk R.J., Nachman P.H., Pendergraft W.F., McGregor J.G.: Gleaning relapse risk from B cell phenotype: decreased CD5+ B cells portend a shorter time to relapse after B cell depletion in patients with ANCA-associated vasculitis. *Ann. Rheum. Dis.*, 2015; 74: 1784-1786
- [13] Calich A.L., Puéchal X., Pugnet G., London J., Terrier B., Charles P., Mouthon L., Guillevin L.: Rituximab for induction and maintenance therapy in granulomatosis with polyangiitis (Wegener's). Results of a single-center cohort study on 66 patients. *J. Autoimmun.*, 2014; 50: 135-141
- [14] Carpenter D.M., Kadis J.A., Devellis R.F., Hogan S.L., Jordan J.M.: The effect of medication-related support on the quality of life of patients with vasculitis in relapse and remission. *J. Rheumatol.*, 2011; 38: 709-715
- [15] Carson K.R., Evens A.M., Richey E.A., Habermann T.M., Focosi D., Seymour J.F., Laubach J., Bawn S.D., Gordon L.I., Winter J.N., Furman R.R., Vose J.M., Zelenetz A.D., Mamtani R., Raisch D.W., et al.: Progressive multifocal leukoencephalopathy after rituximab therapy in HIV-negative patients: a report of 57 cases from the Research on Adverse Drug Events and Reports project. *Blood*, 2009; 113: 4834-4840
- [16] Cartin-Ceba R., Golbin J.M., Keogh K.A., Peikert T., Sánchez-Menéndez M., Ytterberg S.R., Fervenza F.C., Specks U.: Rituximab for remission induction and maintenance in refractory granulomatosis with polyangiitis (Wegener's): ten-year experience at a single center. *Arthritis Rheum.*, 2012; 64: 3770-3778
- [17] CCX168 Phase II Data in ANCA-Associated Renal Vasculitis. <http://ir.chemocentryx.com/releasedetail.cfm?ReleaseID=811237> (28.02.2016)
- [18] de Groot K., Harper L., Jayne D.R., Flores Suarez L.F., Gregorini G., Gross W.L., Luqmani R., Pusey C.D., Rasmussen N., Sinico R.A., Tesar V., Vanhille P., Westman K., Savage C.O.: Pulse versus daily oral cyclophosphamide for induction of remission in antineutrophil cytoplasmic antibody-associated vasculitis: a randomized trial. *Ann. Intern. Med.*, 2009; 150: 670-680
- [19] de Groot K., Rasmussen N., Bacon P.A., Tervaert J.W., Feighery C., Gregorini G., Gross W.L., Luqmani R., Jayne D.R.: Randomized trial of cyclophosphamide versus methotrexate for induction of remission in early systemic antineutrophil cytoplasmic antibody-associated vasculitis. *Arthritis Rheum.*, 2005; 52: 2461-2469
- [20] de Joode A.A., Sanders J.S., Smid W.M., Stegeman C.A.: Plasmapheresis rescue therapy in progressive systemic ANCA-associated vasculitis: single-center results of stepwise escalation of immunosuppression. *J. Clin. Apher.*, 2014; 29: 266-272
- [21] Draibe J., Poveda R., Fulladosa X., Vidaller A., Zurberti C., Goma M., Pujol R., Ripoll E., Torras J., Grinyó J.M.: Use of mycophenolate in ANCA-associated renal vasculitis: 13 years of experience at a university hospital. *Nephrol. Dial. Transplant.*, 2015; 30: 132-137
- [22] Eisenberger U., Fakhouri F., Vanhille P., Beaufile H., Mahr A., Guillevin L., Lesavre P., Noël L.H.: ANCA-negative pauci-immune renal vasculitis: histology and outcome. *Nephrol. Dial. Transplant.*, 2005; 20: 1392-1399
- [23] European Vasculitis Study Group. Clinical Trial Protocol: REMA-IN. <http://www.vasculitis.org/images/documents/remain%20jan%202006.pdf> (28.02.2016)
- [24] Falk R.J.: Identification and management of relapsing disease in granulomatosis with polyangiitis and microscopic polyangiitis. In: *UpToDate*, eds.: R.J. Glassock, G.B. Appel. *UpToDate*, Waltham, Massachusetts
- [25] Falk R.J.: Maintenance immunosuppressive therapy in granulomatosis with polyangiitis and microscopic polyangiitis. In: *UpToDate*, eds.: G.B. Appel, F.C. Fervenza. *UpToDate*, Waltham, Massachusetts
- [26] Falk R.J.: Prognosis in granulomatosis with polyangiitis and microscopic polyangiitis, and management of those who develop end-stage renal disease. In: *UpToDate*, eds.: G.B. Appel, F.C. Fervenza. *UpToDate*, Waltham, Massachusetts
- [27] Flossmann O., Baslund B., Bruchfeld A., Tervaert J.W., Hall C., Heinzel P., Hellmich B., Luqmani R.A., Nemoto K., Tesar V., Jayne D.R.: De-



oxyspergualin in relapsing and refractory Wegener's granulomatosis. *Ann. Rheum. Dis.*, 2009; 68: 1125-1130

- [28] Flossmann O., Berden A., de Groot K., Hagen C., Harper L., Heijl C., Höglund P., Jayne D., Luqmani R., Mahr A., Mukhtyar C., Pusey C., Rasmussen N., Stegeman C., Walsh M., et al.: Long-term patient survival in ANCA-associated vasculitis. *Ann. Rheum. Dis.* 2011; 70: 488-494
- [29] Furuta S., Jayne D.R.: Antineutrophil cytoplasm antibody-associated vasculitis: recent developments. *Kidney Int.*, 2013; 84: 244-249
- [30] Galesic K., Ljubanovic D., Horvatic I.: Treatment of renal manifestations of ANCA-associated vasculitis. *J. Nephropathol.*, 2013; 2: 6-19
- [31] Geetha D., Specks U., Stone J.H., Merkel P.A., Seo P., Spiera R., Langford C.A., Hoffman G.S., Kallenberg C.G., St Clair E.W., Fessler B.J., Ding L., Tchao N.K., Ikle D., et al.: Rituximab versus cyclophosphamide for ANCA-associated vasculitis with renal involvement. *J. Am. Soc. Nephrol.*, 2015; 26: 976-985
- [32] Gigante A., Gasperini M.L., Barbano B., Liberatori M., Sardo L., Jovanovic T., Giannakakis K., Cianci R., Amoroso A.: Gabexate mesylate as treatment in the course of ANCA-negative microscopic polyangiitis. *Ren. Fail.*, 2013; 35: 721-724
- [33] Gregersen J.W., Kristensen T., Krag S.R., Birn H., Ivarsen P.: Early plasma exchange improves outcome in PR3-ANCA-positive renal vasculitis. *Clin. Exp. Rheumatol.*, 2012; 30: S39-S47
- [34] Guerry M.J., Brogan P., Bruce I.N., D'Cruz D.P., Harper L., Luqmani R., Pusey C.D., Salama A.D., Scott D.G., Savage C.O., Watts R.A., Jayne D.R.: Recommendations for the use of rituximab in anti-neutrophil cytoplasm antibody-associated vasculitis. *Rheumatology*, 2012; 51: 634-643
- [35] Guillevin L., Pagnoux C., Karras A., Khouatra C., Aumaitre O., Cohen P., Maurier F., Decaux O., Ninet J., Gobert P., Quémeuneur T., Blanchard-Delaunay C., Godmer P., Puéchal X., Carron P.L., et al.: Rituximab versus azathioprine for maintenance in ANCA-associated vasculitis. *N. Engl. J. Med.*, 2014; 371: 1771-1780
- [36] Han F., Liu G., Zhang X., Li X., He Q., He X., Li Q., Wang S., Wang H., Chen J.: Effects of mycophenolate mofetil combined with corticosteroids for induction therapy of microscopic polyangiitis. *Am. J. Nephrol.*, 2011; 33: 185-192
- [37] Harper L., Morgan M.D., Walsh M., Hoglund P., Westman K., Flossmann O., Tesar V., Vanhille P., de Groot K., Luqmani R., Flores-Suarez L.F., Watts R., Pusey C., Bruchfeld A., Rasmussen N., et al.: Pulse versus daily oral cyclophosphamide for induction of remission in ANCA-associated vasculitis: long-term follow-up. *Ann. Rheum. Dis.*, 2012; 71: 955-960
- [38] Harper L., Savage C.O.: ANCA-associated renal vasculitis at the end of the twentieth century - a disease of older patients. *Rheumatology*, 2005; 44: 495-501
- [39] Hasegawa M., Hattori K., Sugiyama S., Asada H., Yamashita H., Takahashi K., Hayashi H., Koide S., Sato W., Yuzawa Y.: A retrospective study on the outcomes of MPO-ANCA-associated vasculitis in dialysis-dependent patients. *Mod. Rheumatol.*, 2016; 26: 110-114
- [40] Hiemstra T.F., Walsh M., Mahr A., Savage C.O., de Groot K., Harper L., Hauser T., Neumann I., Tesar V., Wissing K.M., Pagnoux C., Schmitt W., Jayne D.R.: Mycophenolate mofetil vs azathioprine for remission maintenance in antineutrophil cytoplasmic antibody-associated vasculitis: a randomized controlled trial. *JAMA*, 2010; 304: 2381-2388
- [41] Hogan P.C., O'Connell R.M., Scollard S., Browne E., Hackett E.E., Feighery C.: Biomarkers predict relapse in granulomatosis with polyangiitis. *J. Biomark.*, 2014; 2014: 596503
- [42] Hu W., Liu C., Xie H., Chen H., Liu Z., Li L.: Mycophenolate mofetil versus cyclophosphamide for inducing remission of ANCA vasculitis with moderate renal involvement. *Nephrol. Dial. Transplant.*, 2008; 23: 1307-1312
- [43] Jayne D.: Newer and future treatment of vasculitis. In: *Textbook of systemic vasculitis*, ed.: A. Sharma. Jaypee Brothers Medical Publishers, New Delhi 2015, 238-244
- [44] Jayne D.R., Chapel H., Adu D., Misbah S., O'Donoghue D., Scott D., Lockwood C.M.: Intravenous immunoglobulin for ANCA-associated systemic vasculitis with persistent disease activity. *QJM*, 2000; 93: 433-439
- [45] Jayne D.R., Gaskin G., Rasmussen N., Abramowicz D., Ferrario F., Guillevin L., Mirapeix E., Savage C.O., Sinico R.A., Stegeman C.A., Westman K.W., van der Woude F.J., de Lind van Wijngaarden R.A., Pusey C.D.: Randomized trial of plasma exchange or high-dosage methylprednisolone as adjunctive therapy for severe renal vasculitis. *J. Am. Soc. Nephrol.*, 2007; 18: 2180-2188
- [46] Jayne D., Rasmussen N., Andrassy K., Bacon P., Tervaert J.W., Dardonien J., Ekstrand A., Gaskin G., Gregorini G., de Groot K., Gross W., Hagen E.C., Mirapeix E., Pettersson E., Siegert C., et al.: A randomized trial of maintenance therapy for vasculitis associated with antineutrophil cytoplasmic autoantibodies. *N. Engl. J. Med.*, 2003; 349: 36-44
- [47] Jennette J.C., Falk R.J.: New insight into the pathogenesis of vasculitis associated with antineutrophil cytoplasmic autoantibodies. *Curr. Opin. Rheumatol.*, 2008; 20: 55-60
- [48] Jha V.: Renal and systemic vasculitis. In: *Comprehensive Clinical Nephrology*, eds.: J. Floege, R.J. Johnson, J. Feehally. Saunders, St. Louis, Missouri, 2010, 292-307
- [49] Jones R., Harper L., Ballarín J., Blockmans D., Brogan P., Bruchfeld A., Cid A., Dahlsveen K., Dezoysa J., Lanyon P., Peh C.A., Tesar V., Vaglio A., Walsh M., Walsh D., et al.: A randomized trial of mycophenolate mofetil versus cyclophosphamide for remission induction of ANCA-associated vasculitis: "MYCYC". On behalf of the European vasculitis study group [abstract]. *Presse Med.*, 2013; 42: 678-679
- [50] Jones R.B., Furuta S., Tervaert J.W., Hauser T., Luqmani R., Morgan M.D., Peh C.A., Savage C.O., Segelmark M., Tesar V., van Paassen P., Walsh M., Westman K., Jayne D.R.: Rituximab versus cyclophosphamide in ANCA-associated renal vasculitis: 2-year results of a randomised trial. *Ann. Rheum. Dis.*, 2015; 74: 1178-1182
- [51] Jones R.B., Tervaert J.W., Hauser T., Luqmani R., Morgan M.D., Peh C.A., Savage C.O., Segelmark M., Tesar V., van Paassen P., Walsh D., Walsh M., Westman K., Jayne D.R.: Rituximab versus cyclophosphamide in ANCA-associated renal vasculitis. *N. Engl. J. Med.*, 2010; 363: 211-220
- [52] Joy M.S., Hogan S.L., Jennette J.C., Falk R.J., Nachman P.H.: A pilot study using mycophenolate mofetil in relapsing or resistant ANCA small vessel vasculitis. *Nephrol. Dial. Transplant.*, 2005; 20: 2725-2732
- [53] Kameoka Y., Kishi F., Yamakawa Y., Nagasawa R., Ikeda S., Koura M., Matsuda J., Nakayama T., Suzuki K.: Synthetic immunoglobulin selected from clone library for MPO-ANCA-related vasculitis. *Nephron*, 2015; 129: 145-146 (17th International Vasculitis & ANCA Workshop)
- [54] Karagas M.R., Cushing G.L. Jr, Greenberg E.R., Mott L.A., Spencer S.K., Nierenberg D.W.: Non-melanoma skin cancers and glucocorticoid therapy. *Br. J. Cancer*, 2001; 85: 683-686
- [55] Knight A., Hallenberg H., Baecklund E.: Efficacy and safety of rituximab as maintenance therapy for relapsing granulomatosis with polyangiitis - a case series. *Clin. Rheumatol.*, 2014; 33: 841-848
- [56] Knoll G., Cockfield S., Blydt-Hansen T., Baran D., Kiberd B., Landsberg D., Rush D., Cole E.: Canadian Society of Transplantation consensus guidelines on eligibility for kidney transplantation. *CMAJ*, 2005; 173: S1-S25
- [57] Komatsuda A., Omokawa A., Fujiwara T., Sato R., Togashi M., Okuyama S., Sawada K., Wakui H.: Serum procalcitonin levels in patients with myeloperoxidase-antineutrophil cytoplasmic antibodies-associated glomerulonephritis. *Am. J. Med. Sci.*, 2012; 343: 136-140
- [58] Kötter I., Daikeler T., Amberger C., Tyndall A., Kanz L.: Autologous stem cell transplantation of treatment-resistant systemic vasculitis - a single center experience and review of the literature. *Clin. Nephrol.*, 2005; 64: 485-489
- [59] Kusumoto S., Tanaka Y., Ueda R., Mizokami M.: Reactivation of hepatitis B virus following rituximab-plus-steroid combination chemotherapy. *J. Gastroenterol.*, 2011; 46: 9-16

- [60] Lieberthal J.G., Cuthbertson D., Carette S., Hoffman G.S., Khalidi N.A., Koenig C.L., Langford C.A., Maksimowicz-McKinnon K., Seo P., Specks U., Ytterberg S.R., Merkel P.A., Monach P.A.: Urinary markers in relapsing antineutrophil cytoplasmic antibody-associated vasculitis. *J. Rheumatol.*, 2013; 40: 674-683
- [61] Lionaki S., Hogan S.L., Jennette C.E., Hu Y., Hamra J.B., Jennette J.C., Falk R.J., Nachman P.H.: The clinical course of ANCA small-vessel vasculitis on chronic dialysis. *Kidney Int.*, 2009; 76: 644-651
- [62] Little M.A., Pusey C.D.: Glomerulonephritis due to antineutrophil cytoplasm antibody-associated vasculitis: an update on approaches to management. *Nephrology*, 2005; 10: 368-376
- [63] Lovric S., Erdbruegger U., Kumpers P., Woywodt A., Koenecke C., Wedemeyer H., Haller H., Haubitz M.: Rituximab as rescue therapy in anti-neutrophil cytoplasmic antibody-associated vasculitis: a single-centre experience with 15 patients. *Nephrol. Dial. Transplant.*, 2009; 24: 179-185
- [64] Mansfield N., Hamour S., Habib A.M., Tarzi R., Levy J., Griffith M., Cairns T., Cook H.T., Pusey C.D., Salama A.D.: Prolonged disease-free remission following rituximab and low-dose cyclophosphamide therapy for renal ANCA-associated vasculitis. *Nephrol. Dial. Transplant.*, 2011; 26: 3280-3286
- [65] Marco H., Smith R.M., Jones R.B., Guerry M.J., Catapano F., Burns S., Chaudhry A.N., Smith K.G., Jayne D.R.: The effect of rituximab therapy on immunoglobulin levels in patients with multisystem autoimmune disease. *BMC Musculoskelet. Disord.*, 2014; 15: 178
- [66] McAdoo S., Bedi R., Tarzi R., Griffith M., Pusey C., Cairns T.: Ofatumumab for B cell depletion therapy in ANCA-associated vasculitis. *Nephron*, 2015; 129: 111-112 (17th International Vasculitis & ANCA Workshop)
- [67] McAdoo S.P., Reynolds J., Bhangal G., Smith J., McDaid J.P., Tanna A., Jackson W.D., Masuda E.S., Cook H.T., Pusey C.D., Tam F.W.: Spleen tyrosine kinase inhibition attenuates autoantibody production and reverses experimental autoimmune GN. *J. Am. Soc. Nephrol.*, 2014; 25: 2291-2302
- [68] McGregor J.G., Hogan S.L., Hu Y., Jennette C.E., Falk R.J., Nachman P.H.: Glucocorticoids and relapse and infection rates in anti-neutrophil cytoplasmic antibody disease. *Clin. J. Am. Soc. Nephrol.*, 2012; 7: 240-247
- [69] McGregor J.G., Hogan S.L., Kotzen E.S., Poulton C.J., Hu Y., Negrete-Lopez R., Kidd J.M., Katsanos S.L., Bunch D.O., Nachman P.H., Falk R.J.: Rituximab as an immunosuppressant in antineutrophil cytoplasmic antibody-associated vasculitis. *Nephrol. Dial. Transplant.*, 2015; 30: 123-131
- [70] Medical Outcomes Study: 36-Item Short Form Survey Instrument. http://www.rand.org/health/surveys_tools/mos/mos_core_36item_survey.html (28.02.2016)
- [71] Metzler C., Miehle N., Manger K., Iking-Konert C., de Groot K., Hellmich B., Gross W.L., Reinhold-Keller E.: Elevated relapse rate under oral methotrexate versus leflunomide for maintenance of remission in Wegener's granulomatosis. *Rheumatology*, 2007; 46: 1087-1091
- [72] Miloslavsky E.M., Specks U., Merkel P.A., Seo P., Spiera R., Langford C.A., Hoffman G.S., Kallenberg C.G., St Clair E.W., Tcho N.K., Viviano L., Ding L., Iklé D., Villarreal M., Jepson B., et al.: Rituximab for the treatment of relapses in antineutrophil cytoplasmic antibody-associated vasculitis. *Arthritis Rheumatol.*, 2014; 66: 3151-3159
- [73] Miloslavsky E.M., Specks U., Merkel P.A., Seo P., Spiera R., Langford C.A., Hoffman G.S., Kallenberg C.G., St Clair E.W., Tcho N.K., Viviano L., Ding L., Sejsmundto L.P., Mieras K., Iklé D., et al.: Clinical outcomes of remission induction therapy for severe antineutrophil cytoplasmic antibody-associated vasculitis. *Arthritis Rheum.*, 2013; 65: 2441-2449
- [74] Mohammad A.J., Hot A., Arndt F., Moosig F., Guerry M.J., Amudala N., Smith R., Sivasothy P., Guillevin L., Merkel P.A., Jayne D.R.: Rituximab for the treatment of eosinophilic granulomatosis with polyangiitis (Churg-Strauss). *Ann. Rheum. Dis.*, 2016; 75: 396-401
- [75] Molloy E.S., Calabrese L.H.: Progressive multifocal leukoencephalopathy associated with immunosuppressive therapy in rheumatic diseases: evolving role of biologic therapies. *Arthritis. Rheum.*, 2012; 64: 3043-3051
- [76] Moran S., Little M.A.: Renal transplantation in antineutrophil cytoplasmic antibody-associated vasculitis. *Curr. Opin. Rheumatol.*, 2014; 26: 37-41
- [77] Mukhtyar C., Guillevin L., Cid M.C., Dasgupta B., de Groot K., Gross W., Hauser T., Hellmich B., Jayne D., Kallenberg C.G., Merkel P.A., Rasse H., Salvarani C., Scott D.G., Stegeman C., et al.: EULAR recommendations for the management of primary small and medium vessel vasculitis. *Ann. Rheum. Dis.*, 2009; 68: 310-317
- [78] Nachman P.H., Denu-Ciocca C.J.: Vasculitides. In: *Current Diagnosis and Treatment*, eds.: E.V. Lerma, J.S. Bern, A.R. Nissenson. McGraw-Hill, New York 2008, 265-275
- [79] Nachman P.H., Hogan S.L., Jennette J.C., Falk R.J.: Treatment response and relapse in antineutrophil cytoplasmic antibody-associated microscopic polyangiitis and glomerulonephritis. *J. Am. Soc. Nephrol.* 1996; 7: 33-39
- [80] Nowack R., Göbel U., Klooker P., Hergesell O., Andrassy K., van der Woude F.J.: Mycophenolate mofetil for maintenance therapy of Wegener's granulomatosis and microscopic polyangiitis: a pilot study in 11 patients with renal involvement. *J. Am. Soc. Nephrol.*, 1999; 10: 1965-1971
- [81] Ntatsaki E., Carruthers D., Chakravarty K., D'Cruz D., Harper L., Jayne D., Luqmani R., Mills J., Mooney J., Venning M., Watts R.A.: BSR and BHPR Standards, Guidelines and Audit Working Group. BSR and BHPR guideline for the management of adults with ANCA-associated vasculitis. *Rheumatology*, 2014; 53: 2306-2309
- [82] Pagnoux C., Mahr A., Hamidou M.A., Boffa J.J., Ruivard M., Ducroix J.P., Kyndt X., Lifermann F., Papo T., Lambert M., Le Noach J., Khellaf M., Merrien D., Puéchal X., Vinzio S., et al.: Azathioprine or methotrexate maintenance for ANCA-associated vasculitis. *N. Engl. J. Med.*, 2008; 359: 2790-2803
- [83] Pepper R.J., Draibe J., Tcho N., Lim N., Stone J., Specks U., Merkel P., Salama A.D.: The association of serum calprotectin (S100A8/S100A9) levels with disease relapse in PR3-ANCA-associated vasculitis. *Nephron*, 2015; 129: 95-96 (17th International Vasculitis & ANCA Workshop)
- [84] Pepper R.J., Fabre M.A., Pavesio C., Gaskin G., Jones R.B., Jayne D., Pusey C.D., Salama A.D.: Rituximab is effective in the treatment of refractory Churg-Strauss syndrome and is associated with diminished T-cell interleukin-5 production. *Rheumatology*, 2008; 47: 1104-1105
- [85] Perenyi M., Jayne D.R., Floßmann O.: Gusperimus: immunological mechanism and clinical applications. *Rheumatology*, 2014; 53: 1732-1741
- [86] Puéchal X., Pagnoux C., Perrodeau E., Hamidou M., Boffa J., Knydt X., Liferman F., Papo T., Merrien D., Smail A., Delaval P., Hanrotel-Saliou C., Imbert B., Khouatra C., Lambert M.: Granulomatosis with polyangiitis or microscopic polyangiitis: long-term outcomes of the prospective WEGENT trial comparing azathioprine vs methotrexate for remission-maintenance in 126 patients. *Nephron*, 2015; 129: 80 (17th International Vasculitis & ANCA Workshop)
- [87] Pullerits R., Ljevak M., Vikgren J., Bokarewa M.: Off-trial evaluation of the B cell-targeting treatment in the refractory cases of antineutrophil cytoplasmic antibodies (ANCA)-associated vasculitis: long-term follow-up from a single centre. *Scand. J. Immunol.*, 2012; 76: 411-420
- [88] Rathi M., Sharma A., Nada R.: Renal manifestations. In: *Textbook of systemic vasculitis*, ed.: A. Sharma. Jaypee Brothers Medical Publishers, New Delhi 2015, 157-163
- [89] Rees F., Yazdani R., Lanyon P.: Long-term follow-up of different refractory systemic vasculitides treated with rituximab. *Clin. Rheumatol.*, 2011; 30: 1241-1245
- [90] Rhee E.P., Laliberte K.A., Niles J.L.: Rituximab as maintenance the-



rapy for anti-neutrophil cytoplasmic antibody-associated vasculitis. *Clin. J. Am. Soc. Nephrol.*, 2010; 5: 1394-1400

[91] Roccatello D., Sciascia S., Rossi D., Alpa M., Naretto C., Russo A., Menegatti E., Baldovino S.: Long-term effects of rituximab added to cyclophosphamide in refractory patients with vasculitis. *Am. J. Nephrol.*, 2011; 34: 175-180

[92] Saag K.G., Furst D.E.: Major side effects of systemic glucocorticoids. In: *UpToDate*, ed.: E.L. Matteson. *UpToDate*, Waltham, Massachusetts

[93] Savige J., Gillis D., Benson E., Davies D., Esnault V., Falk R.J., Hagen E.C., Jayne D., Jennette J.C., Paspaliaris B., Pollock W., Pusey C., Savage C.O., Silvestrini R., van der Woude F., et al.: International Consensus Statement on Testing and Reporting of Antineutrophil Cytoplasmic Antibodies (ANCA). *Am. J. Clin. Pathol.*, 1999; 111: 507-513

[94] Schmitt W.H., Hagen E.C., Neumann I., Nowack R., Flores-Suárez L.F., van der Woude F.J.: Treatment of refractory Wegener's granulomatosis with antithymocyte globulin (ATG): an open study in 15 patients. *Kidney Int.*, 2004; 65: 1440-1448

[95] Schönermarck U., Gross W.L., de Groot K.: Treatment of ANCA-associated vasculitis. *Nat. Rev. Nephrol.*, 2014; 10: 25-36

[96] Seo P., Min Y.I., Holbrook J.T., Hoffman G.S., Merkel P.A., Spiera R., Davis J.C., Ytterberg S.R., St Clair E.W., McCune W.J., Specks U., Allen N.B., Luqmani R.A., Stone J.H.: Damage caused by Wegener's granulomatosis and its treatment: prospective data from the Wegener's Granulomatosis Etanercept Trial (WGET). *Arthritis Rheum.*, 2005; 52: 2168-2178

[97] Silva F., Specks U., Kalra S., Hogan M.C., Leung N., Sethi S., Fervenza F.C.: Mycophenolate mofetil for induction and maintenance of remission in microscopic polyangiitis with mild to moderate renal involvement - a prospective, open-label pilot trial. *Clin. J. Am. Soc. Nephrol.*, 2010; 5: 445-453

[98] Sitter T., Schmidt M., Schneider S., Schiffel H.: Differential diagnosis of bacterial infection and inflammatory response in kidney diseases using procalcitonin. *J. Nephrol.* 2002; 15: 297-301

[99] Smith R.M., Jones R.B., Guerry M.J., Laurino S., Catapano F., Chaudhry A., Smith K.G., Jayne D.R.: Rituximab for remission maintenance in relapsing antineutrophil cytoplasmic antibody-associated vasculitis. *Arthritis Rheum.*, 2012; 64: 3760-3769

[100] Specks U., Merkel P.A., Seo P., Spiera R., Langford C.A., Hoffman G.S., Kallenberg C.G., St Clair E.W., Fessler B.J., Ding L., Viviano L., Tchao N.K., Phippard D.J., Asare A.L., Lim N., et al.: Efficacy of remission-induction regimens for ANCA-associated vasculitis. *N. Engl. J. Med.*, 2013; 369: 417-427

[101] Stassen P.M., Tervaert J.W., Stegeman C.A.: Induction of remission in active anti-neutrophil cytoplasmic antibody-associated vasculitis with mycophenolate mofetil in patients who cannot be treated with cyclophosphamide. *Ann. Rheum. Dis.*, 2007; 66: 798-802

[102] Statkute L., Oyama Y., Barr W.G., Sufit R., Ho S., Verda L., Loh Y., Young K., Quigley K., Burt R.K.: Autologous non-myeloablative haematopoietic stem cell transplantation for refractory systemic vasculitis. *Ann. Rheum. Dis.*, 2008; 67: 991-997

[103] Stone J.H., Merkel P.A., Spiera R., Seo P., Langford C.A., Hoffman G.S., Kallenberg C.G., St Clair E.W., Turkiewicz A., Tchao N.K., Webber L., Ding L., Sejmsundo L.P., Mieras K., Weitzkamp D., et al.: Rituximab versus cyclophosphamide for ANCA-associated vasculitis. *N. Engl. J. Med.*, 2010; 363: 221-232

[104] Suppiah R., Mukhtyar C., Flossmann O., Alberici F., Baslund B., Batra R., Brown D., Holle J., Hruskova Z., Jayne D.R., Judge A., Little M.A., Palmisano A., Stegeman C., Tesar V., et al.: A cross-sectional study of the Birmingham Vasculitis Activity Score version 3 in systemic vasculitis. *Rheumatology*, 2011; 50: 899-905

[105] Tang W., Bose B., McDonald S.P., Hawley C.M., Badve S.V., Boudville N., Brown F.G., Clayton P.A., Campbell S.B., Peh C.A., Johnson D.W.: The outcomes of patients with ESRD and ANCA-associated vasculitis in

Australia and New Zealand. *Clin. J. Am. Soc. Nephrol.*, 2013; 8: 773-780

[106] Terrier B., Pagnoux C., Karras A., Khouatra C., Aumaitre O., Cohen P., Maurier F., Decaux O., Demurs-Clavel H., Gobert P.: Rituximab versus azathioprine for maintenance in antineutrophil cytoplasmic antibodies (ANCA)-associated vasculitis (MAINRITSAN): Follow-up at 34 months. *La Presse Médicale*, 2013; 42: 778-779 (16th International Vasculitis & ANCA Workshop)

[107] Thai L.H., Charles P., Resche-Rigon M., Desseaux K., Guillevin L.: Are antiproteinase-3 ANCA a useful marker of granulomatosis with polyangiitis (Wegener's) relapses? Results of a retrospective study on 126 patients. *Autoimmun. Rev.*, 2014; 13: 313-318

[108] Thiel J., Hässler F., Salzer U., Voll R.E., Venhoff N.: Rituximab in the treatment of refractory or relapsing eosinophilic granulomatosis with polyangiitis (Churg-Strauss syndrome). *Arthritis Res. Ther.*, 2013; 15: R133

[109] Tomasson G., Grayson P.C., Mahr A.D., Lavalley M., Merkel P.A.: Value of ANCA measurements during remission to predict a relapse of ANCA-associated vasculitis - a meta-analysis. *Rheumatology*, 2012; 51: 100-109

[110] US National Library of Medicine. *Clinicaltrials.gov*. Belimumab in Remission of VASculitis (BREVAS). <http://clinicaltrials.gov/show/NCT01663623> (28.02.2016)

[111] US National Library of Medicine. *Clinicaltrials.gov*. Comparison Study of Two Rituximab Regimens in the Remission of ANCA Associated Vasculitis (MAINRITSAN 2). <http://clinicaltrials.gov/ct2/show/NCT01731561?term=MAINRITSAN%27&rank=2> (28.02.2016)

[112] US National Library of Medicine. *Clinicaltrials.gov*. Rituximab Vasculitis Maintenance Study (RITAZAREM). <http://clinicaltrials.gov/ct2/show/NCT01697267> (28.02.2016)

[113] van Daalen E., Ferrario F., Noël L.H., Waldherr R., Hagen E.C., Bruijn J.A., Bajema I.M.: Twenty-five years of RENHIS: a history of histopathological studies within EUVAS. *Nephrol. Dial. Transplant.*, 2015; 30: 31-36

[114] Walsh M., Casian A., Flossmann O., Westman K., Höglund P., Pusey C., Jayne D.R.: Long-term follow-up of patients with severe ANCA-associated vasculitis comparing plasma exchange to intravenous methylprednisolone treatment is unclear. *Kidney Int.*, 2013; 84: 397-402

[115] Walsh M., Chaudhry A., Jayne D.: Long-term follow-up of relapsing/refractory anti-neutrophil cytoplasm antibody associated vasculitis treated with the lymphocyte depleting antibody alemtuzumab (CAMPATH-1H). *Ann. Rheum. Dis.* 2008; 67: 1322-1327

[116] Walsh M., Merkel P.A., Peh C.A., Szpirt W., Guillevin L., Pusey C.D., De Zoysa J., Ives N., Clark W.F., Quillen K., Winters J.L., Wheatley K., Jayne D.: Plasma exchange and glucocorticoid dosing in the treatment of anti-neutrophil cytoplasm antibody associated vasculitis (PEXIVAS): protocol for a randomized controlled trial. *Trials*, 2013; 14: 73

[117] Weiner M., Goh S.M., Mohammad A.J., Hruskova Z., Tanna A., Bruchfeld A., Selga D., Chocova Z., Westman K., Eriksson P., Pusey C.D., Tesar V., Salama A.D., Segelmark M.: Outcome and treatment of elderly patients with ANCA-associated vasculitis. *Clin. J. Am. Soc. Nephrol.*, 2015; 10: 1128-1135

[118] Wendt M., Gunnarsson I., Bratt J., Bruchfeld A.: Rituximab in relapsing or refractory ANCA-associated vasculitis: a case series of 16 patients. *Scand. J. Rheumatol.*, 2012; 41: 116-119

[119] Williams M.E., Balogun R.A.: Principles of separation: indications and therapeutic targets for plasma exchange. *Clin. J. Am. Soc. Nephrol.*, 2014; 9: 181-190

[120] Xiao H., Dairaghi D.J., Powers J.P., Ertl L.S., Baumgart T., Wang Y., Seitz L.C., Penfold M.E., Gan L., Hu P., Lu B., Gerard N.P., Gerard C., Schall T.J., Jaen J.C., Falk R.J.: C5a receptor (CD88) blockade protects against MPO-ANCA GN. *J. Am. Soc. Nephrol.*, 2014; 25: 225-231

The authors have no potential conflicts of interest to declare.