

Received: 2014.10.16
Accepted: 2015.11.26
Published: 2016.03.25

EGFR and Bcl-2 in gastric mucosa of children infected with *Helicobacter pylori*

EGFR i Bcl-2 w błonie śluzowej żołądka dzieci zakażonych *Helicobacter pylori*

Authors' Contribution:

- A** Study Design
- B** Data Collection
- C** Statistical Analysis
- D** Data Interpretation
- E** Manuscript Preparation
- F** Literature Search
- G** Funds Collection

Ewa Ryszczuk^{1, B C D E F}, Izabela Roszko-Kirpsza^{1, B D E}, Katarzyna Guzińska-Ustymowicz^{2, B}, Beata Janina Olejnik^{1, B}, Maciej Gustaw Kaczmarek^{3, D E}, Elżbieta Maciorkowska^{1, A B C D E F G}

¹Department of Developmental Age Medicine and Pediatric Nursing, Medical University of Białystok, Poland

²Department of General Pathomorphology, Medical University of Białystok, Poland

³Department of Pediatrics, Gastroenterology and Allergology, Medical University of Białystok, Poland

Summary

The aim of the study was to evaluate the expression of EGFR and Bcl-2 proteins as inhibitory markers of apoptosis in surface epithelial cells and gland cells of antral gastric mucosa in children infected with *Helicobacter pylori* according to the severity and activity of antral gastritis and to assess the correlation between the number of cells expressing EGFR and the number of cells expressing Bcl-2 in *H. pylori* infected children.

Materials and methods:

The study included 44 children: 68.2% with chronic gastritis and positive IgG against *H. pylori*, and 31.8% with functional disorders of the gastrointestinal tract and with normal IgG against *H. pylori*. The evaluation of EGFR expression in gastric mucosa was performed immunohistochemically using monoclonal mouse anti-EGFR antibody. The polyclonal antibody was used to determine the expression of anti-Bcl-2.

Results:

A significant increase in the number of cells expressing EGFR and Bcl-2 protein was found in the epithelial cells in severe as well as mild and moderate gastritis in the group of children infected with *H. pylori*. An increase in the number of cells expressing EGFR and Bcl-2 protein was also found in the epithelial cells in group I according to the activity of gastritis. There was a statistically significant positive correlation between the numbers of cells expressing EGFR and Bcl-2 in *H. pylori* infected children.

Conclusion:

Increased expression of EGFR and Bcl-2 proteins in the epithelial cells and a statistically significant positive correlation between the numbers of cells expressing EGFR and Bcl-2 in *H. pylori* infected children could suggest increased regeneration abilities of gastric mucosa.

Key words:

EGFR • Bcl-2 • children • *H. pylori* • apoptosis



Full-text PDF: <http://www.phmd.pl/fulltxt.php?ICID=1198272>

Word count: 2838

Tables: –

Figures: 5

References: 28

Author's address: prof. dr hab.n.med. Elżbieta Maciorkowska, Department of Developmental Age Medicine and Pediatric Nursing, Medical University of Białystok, 15-295 Białystok, 37 Szpitalna St., Poland; e-mail: emaciorkowska@o2.pl

Abbreviations: **EGFR** – epidermal growth factor receptor; **Bcl-2** – B-cell lymphoma 2

INTRODUCTION

Apoptosis, as a process of programmed death cell, necessary for maintaining intercellular homeostasis, as well as regulating inflammatory processes, is characterized by a complex molecular pathomechanism, which is still not clear.

Apoptosis in the epithelial cells and gland cells of gastric mucosa is activated by two independent pathways:

- the death receptor pathway, also called extrinsic, including receptor CD95 and epidermal growth factor receptor (EGFR) [15]
- the mitochondrial pathway, also called intrinsic, leading to activation of pro-apoptotic (Bax, Bak, Bok, Bad, Bik, Bim, Blk, Noxa, Puma) and anti-apoptotic (Bcl-2, Bcl-xL, Bcl-w, Bcl-B, Mcl-1) proteins. The two groups of proteins are members of the Bcl-2 family of proteins [8].

Both EGFR and Bcl-2 mitochondrial proteins induce cell proliferation and cause chronic inflammatory changes in the gastric mucosa in children infected with *Helicobacter pylori* and are included among inhibitors of apoptosis in pediatric patients [23].

Keates et al. [12] suggest that *H. pylori* can induce phosphorylation of EGFR as a 170 kDa glycoprotein. *H. pylori* intracellular cytotoxin associated gene A protein (CagA) activates the Ras/MAPK/MAPK1 pathway, which results in excessive EGFR-induced cell proliferation [10].

The mechanism of apoptosis inhibition by Bcl-2 and Bcl-xL proteins remains unclear. At this point, it is still unknown whether the effects of Bcl-2 on redox state, Ca²⁺ compartmentalization, protein transport, ion channels and activation of cysteine protease are responsible for controlling a downstream cell death program [3]. Bcl-2 is a proto-oncogene and suppressor of apoptosis. Excessive production of this protein prolongs the life span of cells despite classic apoptotic stimulations [7].

Gastric mucosa cell proliferation induced by EGFR and Bcl-2 mitochondrial protein activation may result in chronic inflammatory changes in the gastric mucosa in adults

infected with *H. pylori*. It is also one of the main cancer-causing factors in adult patients [4,19,21,25]. In children, atrophic changes in the gastric mucosa and intestinal metaplasia are rarely diagnosed. The duration of infection in pediatric patients appears to be too short to cause such changes; therefore *H. pylori* seems to be an etiologic factor in chronic gastritis in children.

The aim of this study is 1/to assess the expression of EGFR and Bcl-2 protein in the epithelial cells and gland cells of antral gastric mucosa in children with *H. pylori* infection (group I) according to the severity and activity of antral gastritis and 2/to evaluate the correlation between the numbers of cells expressing EGFR and Bcl-2 in *H. pylori* infected children.

MATERIALS AND METHODS

Patients

The study included 44 children and adolescents with dyspeptic symptoms such as recurrent abdominal pain, eating disorders, underweight, nausea, and chronic and recurrent vomiting, which indicated gastroscopy.

The patients were divided into two groups depending on the presence and course of *H. pylori* infection. Group I consisted of 30 children (68.2%) with chronic gastritis caused by *H. pylori* infection with a positive titer of IgG antibodies against *H. pylori*, including 14 girls (46.7 %) and 16 boys (53.3 %). The age of patients ranged from 5 to 18 years, and the mean age was 13±3.4 years.

Group II consisted of 14 children (31.8%) with functional disorders of the gastrointestinal tract, without *H. pylori* infection and with a normal IgG level against *H. pylori*, including 7 girls (5%) and 7 boys (5%). The age ranged from 9 to 17 years, and the mean age was 12.8±2.7 years.

The kit “recom Well *Helicobacter* IgG” (Mikrogen GmbH) to detect and identify directly IgG antibodies against *H. pylori* in 44 children and adolescents was based on the immunoenzymatic method ELISA. The antibody concentration IgG ≥ 20 U/ml was regarded as positive.

Before endoscopy, all parents, guardians and children above the age of 14 years gave informed consent for examination. Ethical approval for research was obtained from the local Ethics Committee at the Medical University of Bialystok, Poland.

Endoscopy

Endoscopic examination of the upper gastrointestinal tract was performed, and biopsy samples were taken from the antral gastric mucosa of 30 children with positive IgG against *H. pylori* and 14 children with negative IgG against *H. pylori*. During gastroscopy, a biopsy of mucosa was taken from the antrum of the stomach and a rapid urease test was performed (CLO test for *H. pylori*). The presence of *H. pylori* in gastric mucosal biopsies was detected using a modified Giemsa stain.

Histopathological evaluation was performed based on the updated Sydney Classification of chronic gastritis [6]. The examination was performed using the Q145 Olympus pediatric size gastroscop. General anesthesia was applied in all children under 6 years of age and in uncooperative children. During the examination, biopsy samples of gastric and duodenal mucosa were taken according to current standards.

Histopathological examination

Samples of gastric mucosa were fixed in 10% neutral buffered formalin, embedded in paraffin and cut on a microtome. Histopathological changes were assessed after staining with hematoxylin and eosin (H-E).

The severity and activity of antral gastritis were described in the four-grade updated Sydney Classification. According to this scale, the severity is measured by the presence of mononuclear cells infiltrating the epithelial layers of the gastric mucosa, a half of its thickness or the whole mucosa.

The activity of gastritis was defined based on the number of neutrophils located in the surface layer of mucosa, occupying a half of its thickness or located in the lamina propria, in the epithelial and glandular cells and in the lumen of glands. In the study group of children and adolescents with *H. pylori* infection, the most intensive inflammatory process measured by the severity and activity of inflammation was found in the antral gastric mucosa.

Detection of EGFR and Bcl-2 expression

Specimen preparation for the evaluation of EGFR expression was performed using monoclonal mouse anti-EGFR antibody (EnVision+System-HRP; DAKO). Microscopic preparations were deparaffinized using xylene and subjected to proteinase K activity for 7 minutes. Activity of endogenous peroxidase was blocked via 20-minute incubation of preparations in 3% hydrogen peroxide. After preparations had been washed three times in phosphate

buffer saline, they were incubated with antibody against EGFR in dilution of 1:50 at 37°C.

To reduce binding of nonspecific antibodies, incubation with 0.1% bovine albumin was applied for 15 minutes. The ongoing reaction could be observed by means of diaminobenzidine.

To determine the expression of Bcl-2, polyclonal anti-Bcl-2 antibody (LSAB+System; DAKO) was used. Samples were incubated with the antibody against mitochondrial protein Bcl-2 in dilution of 1:100, for 60 minutes, at room temperature.

The quantitative evaluation of EGFR and Bcl-2 expression in the epithelial and gland cells of antral gastric mucosa was performed using Soft Imaging System Cell B (Olympus). The number of cells showing positive expression of EGFR and Bcl-2 protein, in 4 fields of the samples (Olympus CX41) at 40x magnification, for the control group and group infected with *H. pylori*, in the epithelium and in the mucous glands of antrum was counted. As a result, the number of cells/mm² with positive expression of the studied markers of apoptosis for each of the locations was obtained.

Statistical analysis

The results of laboratory analysis were processed using appropriate statistical tests and calculations. Descriptive statistics in the form of measures of central tendency, including arithmetic mean and median, and a measure of dispersion i.e. standard deviation (SD), were determined for each studied variable and each group of patients.

The Kolmogorov-Smirnov test was used to assess the distribution of the studied variables and showed that they were different from the normal distribution. The non-parametric Mann-Whitney U test was used to analyze differences between the studied groups. The Wilcoxon matched-pairs signed-rank test was applied to measure the dependent variables. The Pearson chi square test of independence was used to evaluate the interdependence between categorical variables. The Spearman rank correlation coefficient was used to analyze the correlations between variables. $p < 0.05$ was considered statistically significant.

The data were analyzed using Statistica 8.0 in the version for personal computers with the operating system Windows.

RESULTS

Histopathological examination of antral mucosa in group I showed moderate gastritis in 56.7% and severe gastritis in 40% of children infected with *H. pylori*. Mild gastritis was found in only 1 child (3.3%). The degree of activity of antral gastritis was determined by measuring neutrophil infiltration and was found to be severe in 20 children



(66.7%), moderate in 9 children (30%) and mild in 1 child (3.3%) in group I.

The analysis of EGFR expression according to the severity of antral gastritis (mild and moderate grade) in children from group I demonstrated a statistically significant ($p < 0.002$) difference between the number of cells with EGFR expression in the epithelium (84.7 ± 14.6 cells/mm²) and in the glands (28.2 ± 23.3 cells/mm²). Also, a significant difference ($p < 0.001$) was found between the number of cells expressing this receptor in the epithelium (79.2 ± 15.4 cells/mm²) and the glands (22.1 ± 21.9 cells/mm²) in children infected with *H. pylori* and severe antral gastritis (Fig. 1).

A comparison of EGFR expression in the epithelial and

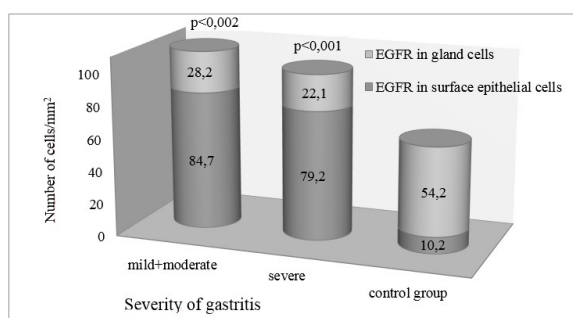


Fig. 1. Expression of EGFR in epithelial cells and gland cells of the antral gastric mucosa according to the severity of gastritis

gland cells of the antral gastric mucosa according to the activity of gastritis also showed a higher amount of cells expressing this receptor in the epithelium as compared to the glands. The same finding was revealed when assessing the EGFR expression according to the degree of severity of antral gastritis (Fig. 1, 2).

In group I, with mild and moderate activity of antral gastritis, the number of cells with EGFR expression in the epithelium (mean 85.7 ± 10.9 cells/mm²) was higher than the number of cells with EGFR expression in the glands (mean 32.4 ± 26.0 cells/mm²) of antral gastric mucosa (Fig. 2).

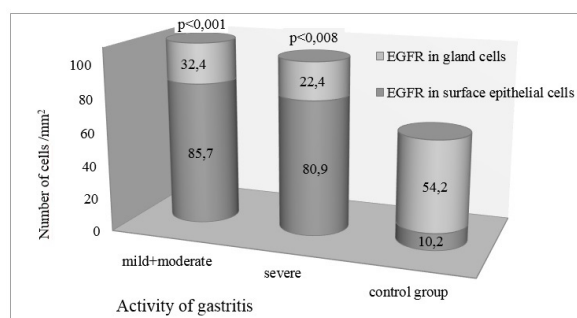


Fig. 2. Expression of EGFR in epithelial cells and gland cells of the antral gastric mucosa according to the activity of gastritis

A significant difference ($p < 0.008$) was also found between the number of cells with EGFR expression in the epithelium (mean 80.9 ± 16.6 cells/mm²) and in the gastric mucous glands (mean 22.4 ± 20.6 cells/mm²) in group I, with severe activity of antral gastritis (Fig. 2).

Evaluation of Bcl-2 expression in epithelial and gland cells of antral gastric mucosa according to the severity of gastritis in children from group I also confirmed the presence of a significant difference between the number of cells with Bcl-2 expression in children with mild and moderate ($p < 0.003$), and also severe gastritis ($p < 0.001$) (Fig. 3).

A comparison of Bcl-2 expression in the epithelial and gland cells of the antral gastric mucosa in children from group I according to the activity of antral gastritis showed that the number of cells expressing this protein was also higher in the epithelium as compared to the glands (Fig. 4). The same was found when assessing the Bcl-2 expression according to the degree of severity of antral gastritis (Fig. 3,4).

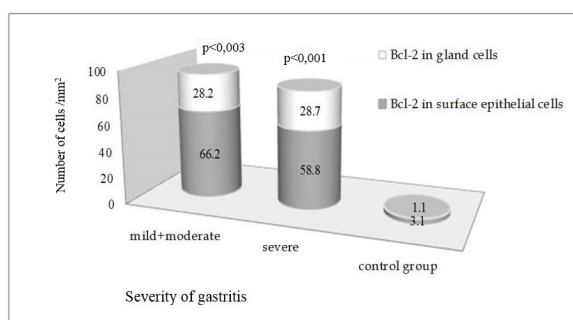


Fig. 3. Expression of Bcl-2 protein in epithelial cells and gland cells of the antral gastric mucosa according to the severity of gastritis

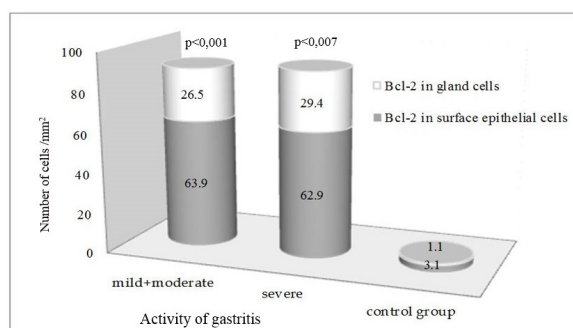


Fig. 4. Expression of Bcl-2 protein in epithelial cells and gland cells of the antral gastric mucosa according to the activity of gastritis

A significant difference was also found between the number of cells with Bcl-2 expression in the epithelium and in the antral gastric glands in children infected with *H. pylori* and antral gastritis activity of mild and moderate ($p < 0.001$), and also severe degree ($p < 0.007$) (Fig. 4).

The analysis of correlations between the studied markers of apoptosis in group I revealed the presence of a positive correlation ($p < 0.01$; $r = 0.459$) between the number of cells expressing Bcl-2 and the number of cells expressing EGFR in the glands of antral gastric mucosa (Fig. 5).

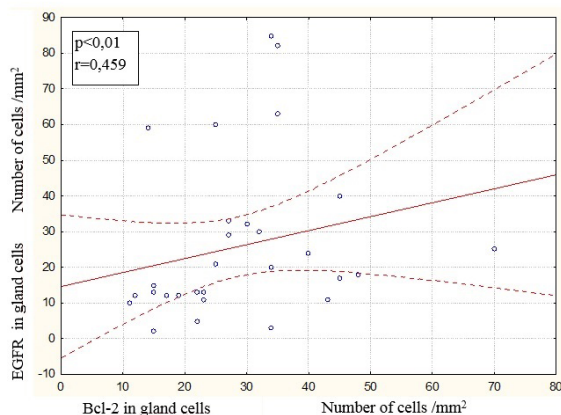


Fig. 5. Correlation between expression of Bcl-2 and EGFR in gland cells of children infected H. pylori

DISCUSSION

The inflammatory changes in the course of H. pylori infection in children are most frequently located in the antral gastric mucosa, as indicated by many authors [13,14,18]. Severity and activity of antral gastritis in the course of H. pylori infection are most often diagnosed as moderate and/or severe, and only in a small number of patients is the diagnosis mild gastritis.

Most studies have suggested that H. pylori in vivo and in vitro may induce apoptosis of cells. H. pylori induced VacA toxin, lipopolysaccharide, ammonia, nitric oxide and activates apoptosis through stimulating release of inflammatory mediators [28].

Different morphological changes in gastric mucosa and an altered immune response in children with H. pylori infection suggest assessing the expression of an individual receptor and mitochondrial markers of apoptosis, and at the same time, analyzing histopathological changes in the antral gastric mucosa of these children. Von Herbay et al. [24] and Xia et al. [26] found an association between the increase in apoptosis induced by H. pylori and the development of chronic gastritis, atrophic gastritis, peptic ulcer formation and intestinal metaplasia.

Kovalenko et al. [13] evaluated a group of 44 children aged between 7 and 15 years, including 24 children with H. pylori infection with clinically diagnosed chronic gastritis, and found that chronic gastritis in children with H. pylori infection was characterized by an increase in the expression of EGFR, which correlated with the severity and activity of gastritis. They stressed the importance of EGFR in the pathogenesis of chronic gastritis in children with

H. pylori infection. According to them, infection with H. pylori causes the increase of EGFR expression, which may result in increased cell proliferation in the gastric mucosa of children infected with H. pylori.

Yan et al. [27] demonstrated that activation of EGFR is a key regulatory step in promoting an antiapoptotic response in gastric epithelial cells infected with H. pylori in vitro and in vivo. H. pylori-induced EGFR activation results in activation of Akt/PI3K kinase activity and regulation of Bcl family members, which promote gastric epithelial cell survival.

Our study confirms a statistically significant increase in the number of cells with EGFR expression in the epithelium of antral gastric mucosa of children in group I in comparison with group II, and shows that infection with H. pylori causes the increase in the expression of EGFR in the studied group of infected children.

Some authors [1,5] emphasize that H. pylori stimulates cell proliferation and causes an increase in the expression of EGFR in gastric mucosa, while others [11,20] indicate that in the course of infection with H. pylori, a decrease in the expression of EGFR and inhibition of cell proliferation is observed. The dualistic influence of H. pylori bacterium on EGFR expression and gastric mucosal cell proliferation, described in the available literature, pertains to adults. There are no results available on the expression of EGFR in the epithelium and glands of the antral gastric mucosa in children that we aimed to analyze in this study.

In addition to the assessment of EGFR in the studies conducted, we analyzed the expression of the mitochondrial protein from the Bcl-2 family, both in the epithelial and gland cells of the antral gastric mucosa of children infected with H. pylori and the correlations between them.

According to Maor-Kendler et al. [16] and Topal et al. [22], the increased expression of anti-apoptotic Bcl-2 protein in the group of adult patients diagnosed with H. pylori-associated chronic gastritis may result in the progression of inflammatory changes and the development of chronic atrophic gastritis.

Maor-Kendler et al. [16] observed an increase in the expression of Bcl-2 protein in 50% of adult patients diagnosed with autoimmune gastritis and concomitant atrophy, and in 45% of patients with H. pylori-associated chronic gastritis and concomitant atrophy. They did not determine the expression of anti-apoptotic Bcl-2 protein in the epithelium in patients with H. pylori-associated chronic gastritis or concomitant atrophy.

Erkan et al. [7] also reported that Bcl-2 expression was higher in the intestinal metaplasia and chronic active gastritis groups than that in the normal gastric mucosa group.

Bartchewsky et al. [2] found significantly higher expression levels of Bcl-2 in gastric mucosa from patients with



chronic gastritis infected by *H. pylori*, as compared with uninfected patients.

Topal et al. [22] confirmed by immunohistochemical analysis the increase in the expression of anti-apoptotic Bcl-2 protein only in 3/32 (9.3%) adult patients diagnosed with chronic gastritis and concomitant atrophy.

According to Guarner et al. [9] and Poniewierka et al. [17], the process of atrophy in the gastric mucosa of pediatric patients is very rarely diagnosed. As presented in the available literature, in adult patients diagnosed with chronic gastritis, the increased expression of anti-apoptotic Bcl-2 protein may lead to intensification of gastritis, resulting in a higher grade of gastric mucosa inflammation or the development of an atrophic process or cancer.

In our study, we found an increase in the expression of anti-apoptotic Bcl-2 protein in both the epithelium and the glands of children infected with *H. pylori* diagnosed with chronic antral gastritis as compared to control children. In the studied children from group I, we also

revealed a statistically significant positive correlation between the numbers of cells expressing Bcl-2 and EGFR in the glands of antral gastric mucosa.

As confirmed by the study results of Yan et al. [27], the anti-apoptotic effect of Bcl-2 mitochondrial protein in the gland cells of the antral gastric mucosa of children infected with *H. pylori* increases the expression of EGFR. The authors demonstrated that infection with *H. pylori*, while causing an increase in the expression of EGFR, increases the anti-apoptotic effect of Bcl-2 mitochondrial protein on the gastric mucosa.

In conclusion, we observed a statistically significant increase in the number of cells expressing EGFR and Bcl-2 protein in the epithelium of antral gastric mucosa of children with *H. pylori*-associated chronic gastritis, which may indicate increased regenerative abilities of gastric mucosa. The positive correlation between the number of cells with EGFR expression and the number of cells with Bcl-2 expression in the infected children suggests the existence of a synergistic effect of anti-apoptotic EGFR and anti-apoptotic Bcl-2.

REFERENCES

- [1] Ashktorab H., Daremipouran M., Wilson M., Siddiqi S., Lee E.L., Rakhshani N., Malekzadeh R., Johnson A.C., Hewitt S.M., Smoot D.T.: Transactivation of the EGFR by AP-1 is induced by *Helicobacter pylori* in gastric cancer. *Am. J. Gastroenterol.*, 2007; 102: 2135-2146
- [2] Bartchewsky W. Jr., Martini M.R., Squassoni A.C., Alvarez M.C., Ladeira M.S., Salvatore D.M., Trevisan M.A., Pedrazzoli J. Jr., Ribeiro M.L.: Effects of *Helicobacter pylori* infection on the expressions of Bax and Bcl-2 in patients with chronic gastritis and gastric cancer. *Dig. Dis. Sci.*, 2010; 55: 111-116
- [3] Basu A., Haldar S.: The relationship between Bcl-2, Bax and p53: consequences for cell cycle progression and cell death. *Mol. Hum. Reprod.*, 1998; 4: 1099-1109
- [4] Bourke B., Jones N., Sherman P.: *Helicobacter pylori* infection and peptic ulcer disease in children. *Pediatr. Infect. Dis. J.*, 1996; 15: 1-13
- [5] Coyle W.J., Sedlack R.E., Nemecek R., Peterson R., Duntemann T., Murphy M., Lawson J.M.: Eradication of *Helicobacter pylori* normalizes elevated mucosal levels of epidermal growth factor and its receptor. *Am. J. Gastroenterol.*, 1999; 94: 2885-2889
- [6] Dixon M.F., Genta R.M., Yardley J.H., Correa P.: Classification and grading of gastritis. The updated Sydney System. International Workshop on the Histopathology of Gastritis, Houston 1994. *Am. J. Surg. Pathol.*, 1996; 20: 1161-1181
- [7] Erkan G., Gonul I.I., Kandilci U., Dursun A.: Evaluation of apoptosis along with BCL-2 and Ki-67 expression in patients with intestinal metaplasia. *Pathol. Res. Pract.*, 2012; 208: 89-93
- [8] Gross A., McDonnell J.M., Korsmeyer S.J.: BCL-2 family members and the mitochondria in apoptosis. *Genes Dev.*, 1999; 13: 1899-1911
- [9] Guarner J., Bartlett J., Whistler T., Pierce-Smith D., Owens M., Kreh R., Czinn S., Gold B.D.: Can pre-neoplastic lesions be detected in gastric biopsies of children with *Helicobacter pylori* infection? *J. Pediatr. Gastroenterol. Nutr.*, 2003; 37: 309-314
- [10] Higashi H., Tsutsumi R., Muto S., Sugiyama T., Azuma T., Asaka M., Hatakeyama M.: SHP-2 tyrosine phosphatase as an intracellular target of *Helicobacter pylori* CagA protein. *Science*, 2002; 295: 683-686
- [11] Jones N.L., Shannon P.T., Cutz E., Yeger H., Sherman P.M.: Increase in proliferation and apoptosis of gastric epithelial cells early in the natural history of *Helicobacter pylori* infection. *Am. J. Pathol.*, 1997; 151: 1695-1703
- [12] Keates S., Sougioultzis S., Keates A.C., Zhao D., Peek R.M. Jr., Shaw L.M., Kelly C.P.: cag+ *Helicobacter pylori* induce transactivation of the epidermal growth factor receptor in AGS gastric epithelial cells. *J. Biol. Chem.*, 2001; 276: 48127-48134
- [13] Kovalenko V.L., Kazachkov E.L., Kazimirov A.A.: Significance of some growth factors in the pathogenesis of chronic gastritis in children. *Arkh. Patol.*, 2008; 70: 3-5
- [14] Maciorkowska E.: Morphological changes in the gastroduodenal mucosa and the concentration of selected cytokines in children with food intolerance, infection with *Helicobacter pylori* and giardiasis. Habilitation thesis. Medical University of Białystok, Białystok 2000
- [15] Maciorkowska E., Guzińska-Ustymowicz K., Ryszczuk E., Kemona A., Kaczmarski M.: The EGFR expression in gastric mucosa of children infected with *Helicobacter pylori*. *Adv. Med. Sci.*, 2009; 54: 187-193
- [16] Maor-Kendler Y., Gabay G., Bernheim J., Naftali T., Lesin I., Leichtman G., Pomeranz I., Novis B.: Expression of bcl-2 in autoimmune and *Helicobacter pylori*-associated atrophic gastritis. *Dig. Dis. Sci.*, 1999; 44: 680-685
- [17] Poniewierka E., Rzeszutko M., Gosciniak G.: Relationship between the infection with *Helicobacter pylori* and histopathological picture of gastric mucosa evaluated in accordance with the Sydney classification. *Post. Med.*, 1996; 5: 51-56
- [18] Roszko I.: *Helicobacter pylori* infection in family members in the population of north-eastern Poland – morphological and molecular genetic studies. PhD thesis. Medical University of Białystok, Białystok 2006
- [19] Rotim O., Nduduba D.A., Otegbeye F.M.: *Helicobacter pylori* and the pathogenesis of gastroduodenal disease: implications for

the management of peptic ulcer disease. *Niger Postgrad. Med. J.*, 2005; 12: 289-298

[20] Ruzsovcics A., Unger Z., Molnar B., Pronai L., Tulassay Z.: Effect of *Helicobacter pylori* infection on epidermal growth factor receptor (EGFR) expression and cell proliferation of gastric epithelial mucosa: correlation to macroscopic and microscopic diagnosis. *Int. J. Exp. Pathol.*, 2002; 83: 257-263

[21] Sipponen P.: *Helicobacter pylori* gastritis - epidemiology. *J. Gastroenterol.*, 1997; 32: 273-277

[22] Topal D., Göral V., Yilmaz F., Kara I.H.: The relation of *Helicobacter pylori* with intestinal metaplasia, gastric atrophy and BCL-2. *Turk. J. Gastroenterol.*, 2004; 15: 149-155

[23] Voldborg B.R., Damstrup L., Spang-Thomsen M., Poulsen H.S.: Epidermal growth factor receptor (EGFR) and EGFR mutations, function and possible role in clinical trials. *Ann. Oncol.*, 1997; 8: 1197-1206

[24] Von Herbay A., Rudi J.: Role of apoptosis in gastric epithelial turnover. *Microsc. Res. Tech.*, 2000; 48: 303-311

[25] Wyatt J.I.: Histopathology of gastroduodenal inflammation: the impact of *Helicobacter pylori*. *Histopathology*, 1995; 26: 1-15

[26] Xia H.H., Talley N.J.: Apoptosis in gastric epithelium induced by *Helicobacter pylori* infection: implications in gastric carcinogenesis. *Am. J. Gastroenterol.*, 2001; 96: 16-26

[27] Yan F., Cao H., Chaturvedi R., Krishna U., Hobbs S.S., Dempsey P.J., Peek R.M. Jr., Cover T.L., Washington M.K., Wilson K.T., Polk D.B.: Epidermal growth factor receptor activation protects gastric epithelial cells from *Helicobacter pylori*-induced apoptosis. *Gastroenterology*, 2009; 136: 1297-1307.e3

[28] Zhao Y.Q., Guo T., Qian J.M.: Effects of broth culture filtrate protein of VacA+ *Helicobacter pylori* on the proliferation and apoptosis of gastric epithelial cells. *Chin. Med. J.*, 2013; 126: 2168-2173

The authors have no potential conflicts of interest to declare.

