

Received: 2015.01.25
Accepted: 2015.08.25
Published: 2015.12.02

Authors' Contribution:

- A** Study Design
- B** Data Collection
- C** Statistical Analysis
- D** Data Interpretation
- E** Manuscript Preparation
- F** Literature Search
- G** Funds Collection

Prognostic significance of MCM 2 and Ki-67 in neuroblastic tumors in children*

Znaczenie prognostyczne MCM 2 i Ki-67 w guzach neuroblastycznych u dzieci

Magdalena Lewandowska^{1 A D E}, Katarzyna Taran^{2 B E}, Anna Sitkiewicz^{1 E F},
Ewa Andrzejewska^{1 A E}

¹ Department of Pediatric Surgery and Oncology, Medical University of Lodz

² Department of Pathology, Medical University of Lodz

Summary

Introduction:

Neuroblastic tumors can be characterized by three features: spontaneous regression, maturation and aggressive proliferation. The most common and routinely used method of assessing tumor cell proliferation is to determine the Ki-67 index in the tumor tissue. Despite numerous studies, neuroblastoma biology is not fully understood, which makes treatment results unsatisfactory. MCM 2 is a potential prognostic factor in the neuroblastoma group.

Material/Methods:

The study is based on retrospective analysis of 35 patients treated for neuroblastic tumors in the Department of Pediatric Surgery and Oncology of the Medical University of Lodz, during the period 2001-2011. The material comprised tissues of 16 tumors excised during the operation and 19 biopsy specimens. Immunohistochemical examinations were performed with immunoperoxidase using mouse monoclonal anti-MCM 2 and anti-Ki-67 antibodies.

Results:

We observed that MCM 2 expression ranged from 2% to 98% and the Ki-67 index ranged from 0 to 95%. There was a statistically significant correlation between expression of MCM 2 and the value of the Ki-67 index and a correlation close to statistical significance between expression of MCM 2 and unfavorable histopathology. There was no statistical relationship between expression of MCM 2 and age over 1 year and N-myc amplification.

Discussion:

The presented research shows that MCM 2 may have prognostic significance in neuroblastic pediatric tumors and as a potential prognostic factor could be the starting point of new individualized therapy.

Keywords:

MCM 2 • neuroblastoma • prognostic factor

Full-text PDF:

<http://www.phmd.pl/fulltxt.php?ICID=1184450>

Word count:

2703

Tables:

2

Figures:

1

References:

42

Author's address:

lek. Magdalena Lewandowska, Department of Pediatric Surgery and Oncology Medical University of Lodz, ul. Niecała 3 m. 23 95-200 Pabianice; e-mail: mlewandosia@o2.pl

*Supported by Grant of Medical University of Lodz No. 502-03/1-123-01/502-14-080.

INTRODUCTION

Neuroblastoma (NB) accounts for 8-11% of all pediatric malignant neoplasms. It is one of the most common childhood solid extracranial tumors, and it is the most common malignant neoplasm of newborns and infants [21]. Over 85% of tumors of this type appear during the first 4 years of age, and 50% of tumors occur before the second year of life. In about 48% of children presence of the metastasis is found at the time of diagnosis; 60-70% of cases are diagnosed in the highest clinical stage, IV [29,31]. In terms of histopathology studies, the neuroblastoma group includes neuroblastoma, ganglioneuroblastoma, and ganglioneuroma.

The prognosis of neuroblastic tumors is conditioned by many factors. Recognized prognostic factors are as follows: clinical stage according to INSS (International Neuroblastoma Staging System); levels of catecholamines, neuron-specific enolase, ferritin, lactate dehydrogenase in the blood serum and vanillylmandelic and homovanillic acid in the urine, higher concentrations of which are associated with worse prognosis. Unfavorable prognostic factors are as follows: amplification of the N-myc oncogene (more than 10 copies of the gene), high index Ki-67, DNA diploidy and tetraploidy, deletions on chromosomes 1p and 11q. The classification introduced in 2009 by the International Neuroblastoma Risk Group (INRG) extracts histologic category and grade of tumor differentiation as prognostic factors [8]. An independent prognostic factor is the age of the patient. Children under one year have a much better prognosis; the 5-year EFS (event-free survival) rate is 83%. Age and evaluation of prognostic factors allows classification of the patient to the appropriate risk group and implementation of the optimal therapeutic protocol.

Neuroblastic tumors can be characterized by three features: spontaneous regression, maturation and aggressive proliferation. The most common and routinely used method of assessing tumor cell proliferation is to determine the Ki-67 index in the tumor tissue.

The Ki-67 antigen was discovered in 1983 with monoclonal antibodies Ki-67, which were generated by immunizing mice with nuclei of the Hodgkin lymphoma cell line L428. The gene encoding the antigen is localized on chromosome 10. It can be detected in G1, S, G2 and M phase of the cell cycle. It is absent in the resting phase G0, and it only occurs in proliferating cells [37].

The exact role of Ki-67 protein in cell proliferation is not fully understood. It is known to be a necessary phosphoprotein during the reorganization of the nucleus in the middle of mitosis. Ki-67 phosphorylation by the cyclinB/cdc2 complex enables its transport from the interior of the nucleus to the perichromosomal layer at the beginning of mitosis. At the end of the M phase dephosphorylation of the protein occurs. It has been confirmed that in vitro inhibition of proliferation of Ki-67 by inhibitors

of cdc2 kinase blocks mitosis [11,12]. Ki-67 has become a widely used marker for the growth of the cell population, and the antibody directed against it was used in the diagnostics of neoplasm. The proliferation Ki-67 index value reflects the potential possibility of tumor growth.

Despite numerous studies, neuroblastoma biology is not fully understood, which makes treatment results unsatisfactory. Therefore, new prognostic factors, such as extra copies of 17q, ALK (anaplastic lymphoma kinase) overexpression, and telomere length, determination of which could improve treatment results and reduce its side effects, are constantly sought [10,21,24,31,33].

MCM 2 can be a potential prognostic factor in the neuroblastoma group. It belongs to the family of minichromosome maintenance (MCM) proteins, which was identified in the yeast *Saccharomyces cerevisiae* for the first time. Higher eukaryotes include conservative MCM proteins, homologous to the yeast proteins, which are part of the MCM 2-7 complex. MCM 2-7 is involved in the initiation of DNA replication in order to form a pre-replication complex (pre-RC). In the end of the mitosis and at the beginning of the G1 phase, the inactive MCM 2-7 heterohexamer is transported by Cdt 1 protein to the origin of DNA replication, which is marked with the ORC 1-6 complex (origin recognition complex). Then the Cdc 6 protein is attached and the pre-replication complex at the origin of DNA replication is created. At the beginning of S phase, cyclin-dependent kinases activate the MCM 2-7 complex, which becomes active helicase and unwinds DNA double helix. During S phase, Cdt 1 and Cdc 6 are detached from DNA and degraded, which inhibits the formation of the next pre-RC [4,22,26,28,30].

MCM 2 is regarded as a regulatory subunit of the MCM 2-7 complex. It has been shown that a fraction of MCM 2 remains associated with replication foci during a major part of S phase. Loss of MCM protein functions causes DNA damage and genome instability [7,19].

It has been noted that three subunits of the MCM 2-7 complex – MCM 2, MCM 5 and MCM 6 – are more strongly associated with ORC-Cdc 6, and MCM 2 and MCM 5 can create a gate for the entry of the DNA helix into the ring constructed with MCM complex proteins [35]. Researchers examined the process of DNA replication initiation and described the formation of MCM 2-7 double-hexamer. ATP-dependent activation of subunits 2, 5 and 6 causes the connection of the other MCM 2-7 hexamer and facilitates MCM 2-7 dimerization. Incorrect function of MCM 2, 5 and 6 inhibits formation of a stable double-hexamer, which leads to the late arrest of pre-RC complex formation [13,34]. It has been documented that MCM 2-7 complex additionally interacts with DNA α polymerase and stimulates its ability to synthesize RNA primers [42].

It has been shown that MCM proteins, including MCM 2 – the most frequently examined – have a higher specificity and sensitivity than conventional proliferation mark-

ers such as Ki-67 or PCNA [16]. The dependence between MCM 2 protein level and histological type, grade of cell differentiation, clinical stage and prognosis in lung adenocarcinoma has been described [17]. It has been proved that MCM 2 protein can be a promising prognostic factor in renal cell carcinoma, prostate, thyroid cancer and myxofibrosarcoma [3,6,36,39]. Further investigation has shown that this protein can be a more useful proliferation marker than the popular Ki-67 in cancer of the oral cavity, esophagus, stomach and colon [9,15,23,40]. Moreover, as far as women are concerned, the relationship between poor prognosis and MCM 2 expression in breast cancer and ovarian tumors [5,14]. So far little is known about the MCM 2 expression and prognostic significance in pediatric neoplasms.

MATERIAL AND METHODS

The study is based on retrospective analysis of 35 patients treated for neuroblastic tumors in the Department of Pediatric Surgery and Oncology of the Medical University of Lodz, during the period 2001-2011. Six selected histoclinical features – sex, age, clinical stage, histopathology, N-myc amplification, occurrence of death – were assessed.

In the experimental group there were 15 (42.9%) girls and 20 (57.1%) boys. Eleven (31.4%) patients were younger than 1 year of age. The youngest child at the time of diagnosis was 2 weeks old, the oldest 12.5 years old. Clinical stage according to INSS was as follows: stage IV – 13 (37.1%) patients, III stage – 13 (37.1%), II stage – 6 (17.2%), and stage I – 3 (8.6%). N-myc amplification was detected in 6 (17.2%) patients.

The study group was divided into patients with favorable and unfavorable histopathologic diagnosis in accordance with the INRG criteria. The first group included

18 (51.4%) patients, and the other included 17 (48.6%). Twenty-six (74.3%) children from the study group live in remission, and 9 (25.7%) patients died.

The material comprised tissues of 16 tumors excised during the operation and 19 biopsy specimens. Obtained tissues were fixed in 10% formalin and embedded in paraffin blocks. Sections 3-4 µm thick were stained with hematoxylin and eosin (H+E) and used for immunohistochemistry. Immunohistochemical examinations were performed with immunoperoxidase using mouse monoclonal anti-MCM 2 and anti-Ki-67 antibodies. Microscopic image analysis was performed using a Multi Scan Base v. 8.08 image analyzer. All examined microscopic images (Nikon Microphot FXA) were transferred to the computer with a camera (CC20P).

A positive reaction resulted in brown nuclear staining in cells expressing MCM 2 and Ki-67. Expression of MCM 2 and Ki-67 was quantified and presented as an index. In each case 1000 tumor cells were evaluated.

The results were statistically analyzed. For survival analysis, Kaplan-Meier curves were used, and to compare the two groups the log-rank test was applied. To analyze continuous variables or multivariate models, the Cox proportional hazards model was used. The comparison between the groups was made using Student's t-test. The correlation is shown by Spearman's rank correlation coefficient. The difference was considered statistically significant at $p < 0.05$.

RESULTS

We observed that MCM 2 expression ranged from 2% to 98% and the Ki-67 index ranged from 0 to 95%.

In the group of children under 1 year of age MCM 2 expression in tumor tissues was variable, from 2% to 88%, and the Ki-67 index ranged from 0 to 65%, whereas in the group of children over 1 year of age MCM 2 expression in tumor tissues ranged from 2 to 98% and the Ki-67 index ranged from 0 to 95%.

According to the tumor histopathology, MCM 2 expression in tumors of favorable histopathology was variable, from 2% to 83%, and the Ki-67 index ranged from 0 to 53%; MCM 2 expression in tumors of unfavorable histopathology ranged from 4% to 98% and the Ki-67 index ranged from 0 to 95%.

We noted that MCM 2 expression ranged from 7% to 98% in N-myc (+) tumors and from 2% to 98% in N-myc (-) tumors. Ki-67 index values ranged from 27% to 95% in tumors with N-myc amplification and from 27% to 95% in other tumors.

MCM 2 expression in tumors of children in remission was variable, from 2% to 98%. It was the same in tumors of children who died. The Ki-67 index ranged from 0 to 75% in tumors of children in remission and to 95% in tumors of children who died. Details of the statistical analysis are presented in table 1.

There was a statistically significant correlation between expression of MCM 2 and the value of the Ki-67 index and a correlation close to statistical significance between expression of MCM 2 and unfavorable histopathology. There was no statistical relationship between expression of MCM 2 and age over 1 year and N-myc amplification. Statistically significant correlations are shown in table 2.

DISCUSSION

The overall prognosis of patients with NB has markedly improved in recent years, and 5-year survival rates increased from 52% in the 1970s to about 75% in 2000-2005. Nonetheless, NB is the primary cause of death from pediatric cancer for children between the age of one and five years and currently accounts for 13% of deaths. For doctors and scientists it still remains an unknown tumor. On the one hand, in generalized form it is one of the most



difficult tumors to cure, with only 40% long-term survival despite intensive therapy. On the other hand, it can regress completely or mature to ganglioneuroblastoma and ganglioneuroma [21,27]. Hence there is a search for the most accurate knowledge of neuroblastoma cells and new prognostic factors, the discovery of which would increase the effectiveness of therapy.

A statistically significantly high level of MCM 2 was correlated with a high Ki-67 index – a recognized and routinely assessed cellular proliferation index. This is consistent with the results of colon, lung cancer and breast and ovarian cancer studies [5,14,15,17]. MCM 2 protein plays a key role in DNA replication and is considered as a new proliferation marker of prognostic value in oncology, as found in other types of cancer – lung, alimentary tract, ovary, uterine cervix [2,9,14,15,17]. The results of the studies indicate that MCM 2 protein may be of potential prognostic significance also in neuroblastoma. Like the value of Ki-67, the expression level of MCM 2 in our studies correlated with differentiation grade of tumor cells, and the correlation was close to statistical significance. Unfavorable histopathological diagnosis (NB poorly differentiated, NB undifferentiated) was associated with increased expression of the test protein. A similar relationship between tumor differentiation stage and MCM 2 was found in patients with alimentary tract, lung and breast cancer [5,15,17]. However, studies also revealed high expression (above 75%) of MCM 2 in 3 patients with favorable histopathology diagnosis.

In our study, there was no significant dependency between MCM 2 expression and N-myc amplification, although the Ki-67 index correlated with the presence of

N-myc amplification. Amplification of the N-myc oncogene is present in 20% of neuroblastic tumors and is an unfavorable prognostic factor [24]. There has been observed a strong correlation between expression of N-myc and all MCM proteins, and an increase in expression of the MCM 2-7 complex after induction by N-myc was observed. The authors reported that N-myc directly binds to the promoter of MCM genes and induces an increase in the expression of all MCM subunits. It is worth noting that the highest correlation coefficient concerned MCM 2 protein. However, in our study, the patients with N-myc amplification had a high value of MCM 2, which may indicate that the lack of statistical significance may be due to the small size of the test group [25].

The research also revealed no significant relationship between the level of MCM 2 and the age of patients, although in the study group the age of patients over 1 year was significantly associated with worse prognosis. Children under 1 year of age had lower expression of MCM 2 than the older ones. Patients who died in the course of NB were characterized by a higher level of MCM 2 protein than patients who live and remain in remission, but the relationship was not statistically significant.

There is no consensus in the literature about MCM 2 expression and patient death. Earlier investigations revealed a correlation of MCM 2 expression with survival of patients with oral cavity and esophageal squamous cell carcinoma and with glioma [18,23,40]. There was no significant correlation of MCM 2 expression with survival of patients with renal carcinoma, although more deaths were observed in patients with high values of MCM 2 [36].

Table 1. Details of statistical analysis

Characteristics	MCM 2 expression			Ki-67 index		
	Mean [%]	SD [%]	Media [%]n	Mean [%]	SD [%]	Median [%]
The whole group of tumors	41	34	32	33,2	25,98	30
Tumors of children under 1 year	35	34	20	32,4	20,76	36
Tumors of children over 1 year	44	34	37	33,6	28,45	28,5
Tumors of favorable histopathology	32	27	28	20,2	17,68	21
Tumors of unfavorable histopathology	52	37	67	46,9	26,68	44
N-myc (+) tumors	56	38	55	57,2	28,63	48
N-myc (-) tumors	43	33	34	30,4	23,63	28
Tumors of children in remission	38	33	29	29,5	21,17	29
Tumors of children who died	50	37	29	43,8	36,02	48

Table 2. The correlation between prognostic factors of neuroblastoma and MCM 2 expression

MCM 2 expression	Prognostic factor	p
MCM 2 level	Value of Ki-67 index	0.0017
	Unfavorable histopathology diagnosis	0.0665

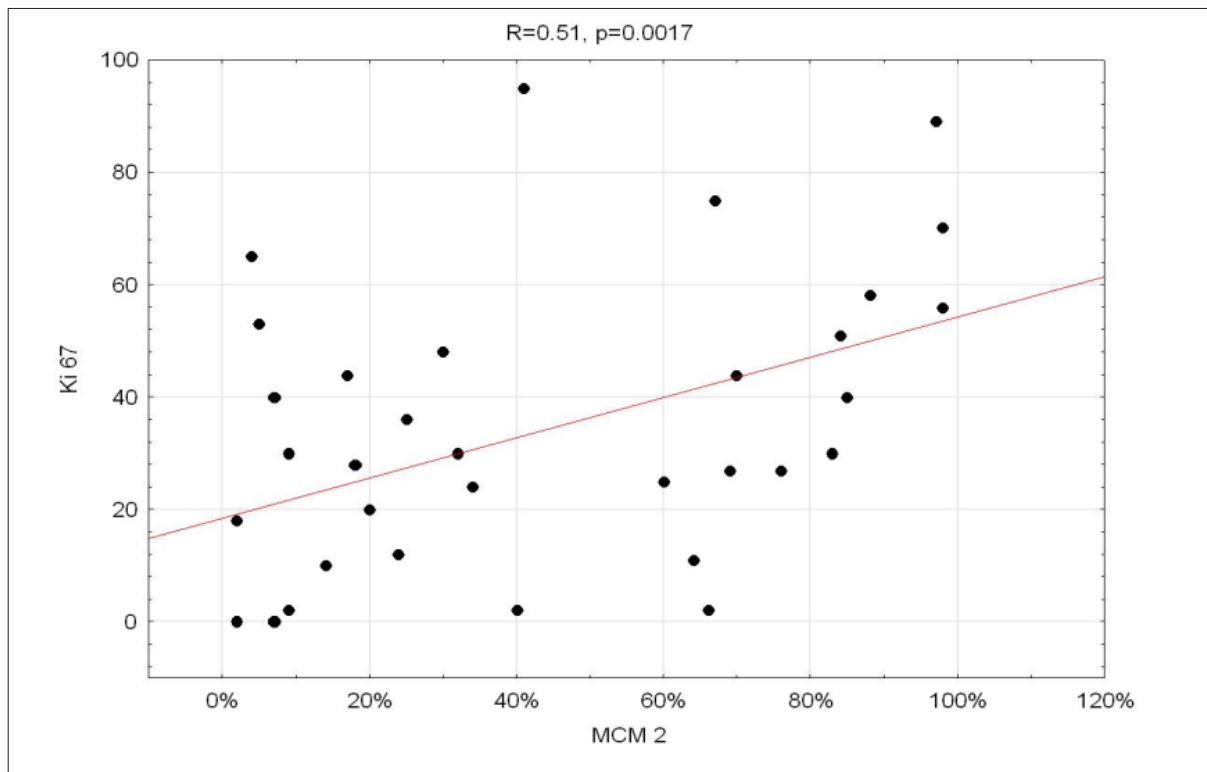


Fig. 1. The correlation between the MCM 2 and the Ki-67 in the study group

It is reported in the literature that MCM 2 expression is higher than Ki-67 in the same lesions. It has been proven in premalignant lesions of the lung and thyroid. Also in our study in each case evaluated prognostic factor values of MCM 2 were higher than values of the proliferation index Ki-67 [6,41]. These results may indicate that MCM 2 allows assessment of the degree of cell proliferation more accurately than Ki-67.

As far as we know, our studies are the first evaluation of MCM 2 expression in neuroblastoma cells. The role of MCM 2 and the potential clinical implications of assessment of its expression require further investigations. The results proved the existence of statistically significant correlations between expression of MCM 2 and recognized prognostic factors in neuroblastoma. The bibliography describes many other aspects of the activity of MCM 2.

The use of MCM proteins allows one to assess the response to therapy in a number of common tumor types. Their utility in the design of new anti-cancer therapies aimed at regulating DNA replication is being studied. The inhibition of MCM 2-7 complex with heli-

quinomycin and ciprofloxacin was described [20,38]. It turned out that MCM 2 protein is also localized in the cytoplasm of the cell, and in response to a replication signal it is transported to the cell nucleus, where it becomes part of the MCM 2-7 complex. It has been shown that MCM 2 bound with retroviral gp 70 protein induces apoptosis of the cell [1].

It means that tumor cells may be more sensitive to DNA damage induced apoptosis by altering the molecular function of MCM 2. This fact makes it possible to search for new therapeutic methods in cancers which have an increased expression of MCM 2. Perhaps further analysis of MCM 2 expression and its impact on the response to treatment will also allow us to search for new therapeutic methods for patients with neuroblastoma.

The presented research shows that MCM 2 may have prognostic significance in neuroblastic pediatric tumors and as a potential prognostic factor could be the starting point of new individualized therapy. Further research is required to understand the role of MCM 2 expression in neuroblastoma biology and evaluate the clinical utility of MCM 2 in the treatment of patients with neoplasms.



REFERENCES

- [1] Abe S., Kurata M., Suzuki S., Yamamoto K., Aisaki K., Kanno J., Kitagawa M.: Minichromosome maintenance 2 bound with retroviral gp70 is localized to cytoplasm and enhances DNA-damage-induced apoptosis. *PLoS One*, 2012; 7: e40129
- [2] Amaro Filho S.M., Nuovo G.J., Cunha C.B., Ramos Pereira L. de O., Oliveira-Silva M., Russomano F., Pires A., Nicol A.F.: Correlation of MCM2 detection with stage and virology of cervical cancer. *Int. J. Biol. Markers*, 2014; 29: 363 - 371
- [3] Ananthanarayanan V., Deaton R.J., Yang X.J., Pins M.R., Gann P.H.: Alteration of proliferation and apoptotic markers in normal and premalignant tissue associated with prostate cancer. *BMC Cancer*, 2006; 6: 73
- [4] Bochman M.L., Schwacha A.: The Mcm complex: unwinding the mechanism of a replicative helicase. *Microbiol. Mol. Biol. Rev.*, 2009; 73: 652-683
- [5] Bukholm I.R., Bukholm G., Holm R., Nesland J.M.: Association between histology grade, expression of HsMCM2, and cyclin A in human invasive breast carcinomas. *J. Clin. Pathol.*, 2003; 56: 368-373
- [6] Cho Mar K., Eimoto T., Nagaya S., Tateyama H.: Cell proliferation marker MCM2, but not Ki67, is helpful for distinguishing between minimally invasive follicular carcinoma and follicular adenoma of the thyroid. *Histopathology*, 2006; 48: 801-807
- [7] Chuang C.H., Yang D., Bai G., Freeland A., Pruitt S.C., Schimenti J.C.: Post-transcriptional homeostasis and regulation of MCM2-7 in mammalian cells. *Nucleic Acids Res.*, 2012; 40: 4914-4924
- [8] Cohn S.L., Pearson A.D., London W.B., Monclair T., Ambros P.F., Brodeur G.M., Faldum A., Hero B., Iehara T., Machin D., Mosseri V., Simon T., Garaventa A., Castel V., Matthay K.K.: The International Neuroblastoma Risk Group (INRG) classification system: an INRG task force report. *J. Clin. Oncol.*, 2009; 27: 289-297
- [9] Czyżewska J., Guzińska-Ustymowicz K., Pryczynicz A., Kemona A., Bandurski R.: Immunohistochemical evaluation of Ki-67, PCNA and MCM2 proteins proliferation index (PI) in advanced gastric cancer. *Folia Histochem. Cytobiol.*, 2009; 47: 289-296
- [10] Drui A.E., Tsauro G.A., Shorikov E.V., Popov A.M., Plekhanova O.M., Tyonogov S.N., Savel'ev L.I., Tsvirenko S.V., Fechina L.G.: Methods of detection and prognostic significance of genetic material increase of the short arm of chromosome 2 and a deletion of the short arm of chromosome 1 in patients with neuroblastoma. *Vopr. Onkol.*, 2013; 59: 591-598
- [11] Endl E., Gerdes J.: The Ki-67 protein: fascinating forms and an unknown function. *Exp. Cell Res.*, 2000; 257: 231-237
- [12] Endl E., Gerdes J.: Posttranslational modifications of the Ki-67 protein coincide with two major checkpoints during mitosis. *J. Cell. Physiol.*, 2000; 182: 371-380
- [13] Evrin C., Fernandez-Cid A., Riera A., Lech J., Clarke P., Herrera M.C., Tognetti S., Lurz R., Speck C.: The ORC/Cdc6/MCM2-7 complex facilitates MCM2-7 dimerization during prereplicative complex formation. *Nucleic Acids Res.*, 2014; 42: 2257-2269
- [14] Gakiopoulou H., Korkolopoulou P., Levidou G., Thymara I., Saetta A., Piperi C., Givalos N., Vassilopoulos I., Ventouri K., Tsenga A., Bamias A., Dimopoulos M.A., Agapitos E., Patsouris E.: Minichromosome maintenance proteins 2 and 5 in non-benign epithelial ovarian tumours: relationship with cell cycle regulators and prognostic implications. *Br. J. Cancer*, 2007; 97: 1124-1134
- [15] Giaginis C., Georgiadou M., Dimakopoulou K., Tsourouflis G., Gatzidou E., Kouraklis G., Theocharis S.: Clinical significance of MCM-2 and MCM-5 expression in colon cancer: association with clinicopathological parameters and tumor proliferative capacity. *Dig. Dis. Sci.*, 2009; 54: 282-291
- [16] Giaginis C., Vgenopoulou S., Vielh P., Theocharis S.: MCM proteins as diagnostic and prognostic tumor markers in the clinical setting. *Histol. Histopathol.*, 2010; 25: 351-370
- [17] Hashimoto K., Araki K., Osaki M., Nakamura H., Tomita K., Shimizu E., Ito H.: MCM2 and Ki-67 expression in human lung adenocarcinoma: prognostic implications. *Pathobiology*, 2004; 71: 193-200
- [18] Hua C., Zhao G., Li Y., Bie L.: Minichromosome maintenance (MCM) family as potential diagnostic and prognostic tumor markers for human gliomas. *BMC Cancer*, 2014; 14: 526
- [19] Ibarra A., Schwob E., Méndez J.: Excess MCM proteins protect human cells from replicative stress by licensing backup origins of replication. *Proc. Natl. Acad. Sci. USA*, 2008; 105: 8956-8961
- [20] Ishimi Y., Sugiyama T., Nakaya R., Kanamori M., Kohno T., Enomoto T., Chino H.: Effect of heliquiren on the activity of human minichromosome maintenance 4/6/7 helicase. *FEBS J.*, 2009; 276: 3382-3391
- [21] Kamijo T., Nakagawara A.: Molecular and genetic bases of neuroblastoma. *Int. J. Clin. Oncol.*, 2012; 17: 190-195
- [22] Kang S., Warner M.D., Bell S.P.: Multiple functions for Mcm2-7 ATPase motifs during replication initiation. *Mol. Cell*, 2014; 55: 655-665
- [23] Kato H., Miyazaki T., Fukai Y., Nakajima M., Sohda M., Takita J., Masuda N., Fukuchi M., Manda R., Ojima H., Tsukada K., Asao T., Kuwano H.: A new proliferation marker, minichromosome maintenance protein 2, is associated with tumor aggressiveness in esophageal squamous cell carcinoma. *J. Surg. Oncol.*, 2003; 84: 24-30
- [24] Kiyonari S., Kadomatsu K.: Neuroblastoma models for insights into tumorigenesis and new therapies. *Expert Opin. Drug Discov.*, 2015; 10: 53-62
- [25] Koppen A., Ait-Aissa R., Koster J., van Sluis P.G., Ora I., Caron H.N., Volckmann R., Versteeg R., Valentijn L.J.: Direct regulation of the minichromosome maintenance complex by MYCN in neuroblastoma. *Eur. J. Cancer*, 2007; 43: 2413-2422
- [26] Kundu L.R., Kumata Y., Kakusho N., Watanabe S., Furukohri A., Waga S., Seki M., Masai H., Enomoto T., Tada S.: Deregulated Cdc6 inhibits DNA replication and suppresses Cdc7-mediated phosphorylation of Mcm2-7 complex. *Nucleic Acids Res.*, 2010; 38: 5409-5418
- [27] Louis C.U., Shohet J.M.: Neuroblastoma: molecular pathogenesis and therapy. *Annu. Rev. Med.*, 2015; 66: 49-63
- [28] Masata M., Juda P., Raska O., Cardoso M.C., Raska I.: A fraction of MCM 2 proteins remain associated with replication foci during a major part of S phase. *Folia Biol.*, 2011; 57: 3-11
- [29] Modak S., Cheung N.K.: Neuroblastoma: therapeutic strategies for a clinical enigma. *Cancer Treat. Rev.*, 2010; 36: 307-317
- [30] Nowińska K., Dzięgiel P.: Białka MCM i ich rola w proliferacji komórek i procesie nowotworowym. *Postępy Hig. Med. Dośw.*, 2010; 64: 627-635
- [31] Ohali A., Avigad S., Ash S., Goshen Y., Luria D., Feinmesser M., Zaizov R., Yaniv I.: Telomere length is a prognostic factor in neuroblastoma. *Cancer*, 2006; 107: 1391-1399
- [32] Parodi F., Passoni L., Massimo L., Luksch R., Gambini C., Rossi E., Zuffardi O., Pistoia V., Pezzolo A.: Identification of novel prognostic markers in relapsing localized resectable neuroblastoma. *OMICS*, 2011; 15: 113-121
- [33] Passoni L., Longo L., Collini P., Coluccia A.M., Bozzi F., Podda M., Gregorio A., Gambini C., Garaventa A., Pistoia V., Del Grosso F., Tonini G.P., Cheng M., Gambacorti-Passerini C., Anichini A., et al.: Mutation-independent anaplastic lymphoma kinase overexpression in poor

prognosis neuroblastoma patients. *Cancer Res.*, 2009; 69: 7338-7346

[34] Riera A., Fernandez-Cid A., Speck C.: The ORC/Cdc6/MCM2-7 complex, a new power player for regulated helicase loading. *Cell Cycle*, 2013; 12: 2155-2156

[35] Riera A., Li H., Speck C.: Seeing is believing: the MCM 2-7 complex helicase trapped in complex with its DNA loader. *Cell Cycle*, 2013; 12: 2917-2918

[36] Rodins K., Cheale M., Coleman N., Fox S.B.: Minichromosome maintenance protein 2 expression in normal kidney and renal cell carcinomas: relationship to tumor dormancy and potential clinical utility. *Clin. Cancer Res.*, 2002; 8: 1075-1081

[37] Scholzen T., Gerdes J.: The Ki-67 protein: from the known and the unknown. *J. Cell. Physiol.*, 2000; 182: 311-322

[38] Simon N., Bochman M.L., Seguin S., Brodsky J.L., Seibel W.L., Schwacha A.: Ciprofloxacin is an inhibitor of the MCM2-7 replicative helicase. *Biosci. Rep.*, 2013; 33: 783-795

[39] Singleton J.D., Freeman A., Morris L.S., Vowler S.L., Arch B.N., Fisher C., Coleman N.: Minichromosome maintenance protein in myxofibrosarcoma. *Mod. Pathol.*, 2004; 17: 235-240

[40] Szelachowska J., Dziegiel P., Jelen-Krzyszewska J., Jelen M., Matkowski R., Pomiecko A., Szytkowska B., Jagas M., Gisterek I., Kornafel J.: Mcm-2 protein expression predicts prognosis better than Ki-67 antigen in oral cavity squamocellular carcinoma. *Anticancer Res.*, 2006; 26: 2473-2478

[41] Tan D.F., Huberman J.A., Hyland A., Loewen G.M., Brooks J.S., Beck A.F., Todorov I.T., Bepler G.: MCM2-a promising marker for pre-malignant lesions of the lung: a cohort study. *BMC Cancer*, 2001; 1: 6

[42] You Z., De Falco M., Kamada K., Pisani F.M., Masai H.: The Minichromosome maintenance (Mcm) complexes interact with DNA polymerase α -primase and stimulate its ability to synthesize RNA primers. *PLoS One*, 2013; 8: e72408

The authors have no potential conflicts of interest to declare.

