

Received: 2011.08.04  
Accepted: 2011.09.23  
Published: 2011.10.10

## A rare variant route of the ulnar artery does not contraindicate the creation of a fistula in the wrist of a diabetic patient with end-stage renal disease

Rzadka odmiana przebiegu tętnicy łokciowej nie jest przeciwwskazaniem do wytworzenia przetoki w okolicy nadgarstka u pacjenta ze schyłkową niewydolnością nerek w przebiegu cukrzycy

Mirosław Banasik<sup>1ABDEF</sup>, Katarzyna Madziarska<sup>1ABDE</sup>, Wacław Weyde<sup>1ABDEFG</sup>,  
Mariusz Kusztal<sup>1BDEF</sup>, Tomasz Gołębiowski<sup>1BDF</sup>, Sławomir Zmonarski<sup>1BDF</sup>,  
Magdalena Krajewska<sup>1ABD</sup>, Dariusz Janczak<sup>2ABD</sup>, Marian Klinger<sup>1ADEF</sup>

<sup>1</sup> Department of Nephrology and Transplantation Medicine

<sup>2</sup> Department of Vascular, General and Transplantation Surgery, Wrocław Medical University, Wrocław, Poland

### Summary

A superficial variant route of the ulnar artery is a rare variation of the arterial system of the wrist. The route of the arteries in that region is extremely important for patients with end-stage renal disease due to the necessity to create an arteriovenous fistula for hemodialysis. It is thought that the vascular access is too often achieved by catheters or vascular prostheses because of that each possibility to create a fistula in the wrist region should be utilized. In our patient a rare variant route of the ulnar artery was observed in the wrist region. Instead of a deep route between the muscles the artery did not only run superficially, but, also untypically, first laterally and then medially. A variation of the ulnar artery's route may evoke a fear of hand ischemia after creation arteriovenous fistula for hemodialysis. The fear may be connected with blood supply through the palmar arch which is created by radial and ulnar artery. This fear of the doctor may result in avoiding the attempt to create an arteriovenous fistula on the wrist. The authors demonstrate that the variant route of the ulnar artery is not a contraindication to the creation of a fistula on the wrist using the radial artery because of a fear of hand ischemia.

**Key words:** hemodialysis • vascular access • ulnar artery

### Streszczenie

Powierzchniowy wariant przebiegu tętnicy łokciowej jest rzadką odmianą układu tętniczego w okolicy nadgarstka. Przebieg tętnic w tej okolicy jest niezmiernie ważny dla pacjentów ze schyłkową niewydolnością nerek z powodu konieczności wytworzenia przetoki tętniczo-żylniej do celów hemodializy. Uważa się, iż dostęp naczyniowy jest zbyt często wytwarzany z użyciem cewników i protez naczyniowych dlatego każda możliwość wytworzenia dostępu z własnych naczyń powinna zostać wykorzystana. U naszego pacjenta rzadką odmianę przebiegu tętnicy łokciowej zaobserwowano w okolicy nadgarstka. Zamiast głębokiego przebiegu między mięśniami, tętnica nie tylko przebiegała powierzchownie, ale również nietypowo – początkowo bocznie, a następnie

przyśrodkowo. Taki wariant przebiegu tętnicy łokciowej może wzbudzić obawę niedokrwienia ręki w następstwie wytworzenia przetoki tętniczo-żylnej do hemodializ. Obawa może się wiązać z zaopatrzeniem w krew łuku dłoniowego utworzonego przez tętnicę promieniową oraz łokciową. Obawa lekarzy może w konsekwencji doprowadzić do odstąpienia od próby wytworzenia przetoki tętniczo-żylnej w okolicy nadgarstka. Autorzy udowadniają, iż przedstawiony wariant przebiegu tętnicy łokciowej nie jest przeciwwskazaniem do wytworzenia przetoki w okolicy nadgarstka z użyciem tętnicy promieniowej i nie ma powodu do obaw o niedokrwienie ręki.

**Słowa kluczowe:** hemodializa • dostęp naczyniowy • tętnica łokciowa

**Full-text PDF:** <http://www.phmd.pl/fulltxt.php?ICID=962525>

**Word count:** 1007

**Tables:** –

**Figures:** 3

**References:** 16

**Author's address:** Mirosław Banasik MD PhD, Department of Nephrology and Transplantation Medicine, Wrocław Medical University, ul. Borowska 213, 50-556 Wrocław; e-mail: m.banasik@interia.pl

## BACKGROUND

A superficial course of ulnar artery on the forearm is a rare variation, with an incidence of 0.7–7% [4,5,12]. This region is extremely important in patients with end-stage renal disease because of the necessity of arteriovenous fistula creation for hemodialysis. The classical Cimino-Brescia fistula is without doubt the best vascular access in chronically hemodialysed patients [6,9,14]. Analyses show that vascular access is too often achieved by means of catheters or vascular prostheses. A variation of the ulnar artery's route may evoke a fear of hand ischemia after creation arteriovenous fistula for hemodialysis. This unfounded fear of the doctor may result in avoiding the attempt to create an arteriovenous fistula on the wrist. The fear may be connected with blood supply through the palmar arch which is created by radial and ulnar artery. After classic arteriovenous fistula creation end-to-end or rarer end-to-back hand ischemia may be observed but even in a described case standard Allen test is adequate to check the blood supply. A superficial ulnar artery may be also mistaken for veins and can show the way to intra-arterial injection of drugs [3,7]. A superficial artery is in addition more vulnerable to trauma.

Variations in the arterial system of the upper limb are well documented [1,3,8,10,13]. Our own experience allowed us to determine that variation of the radial artery does not restrict the successful creation of an arteriovenous fistula for hemodialysis [16]. The importance of vascular abnormalities in patients with autosomal dominant polycystic kidney disease who require the creation of an arteriovenous fistula was noted earlier by our group [15].

In this paper we present that this variant route of the ulnar artery should not be a contraindication to the creation of a fistula on the wrist of a diabetic patient with end-stage renal disease.

## CASE PRESENTATION

A 63-year-old man was admitted to the hospital because of end-stage renal disease. The patient had suffered from diabetes for 28 years and was being treated for hypertension. Deterioration of renal function had been detected 5 years before.

It was decided that hemodialysis would be the appropriate method of renal replacement therapy for this patient and vascular access creation was planned. During examination

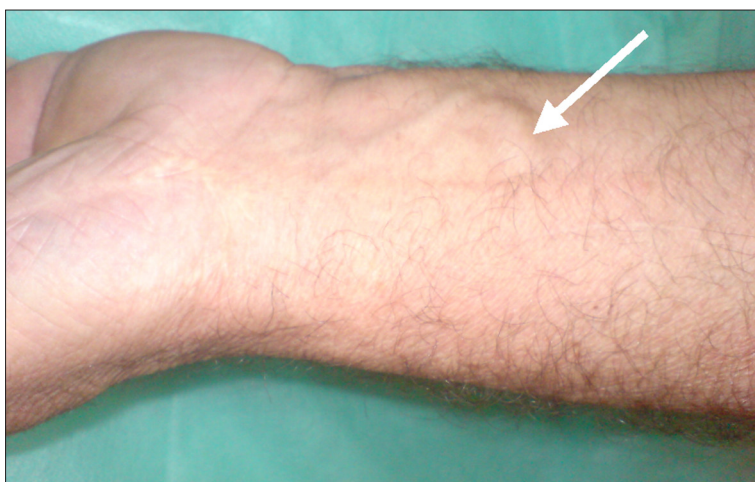

Fig. 1. The superficial variant route of the ulnar artery (arrow)

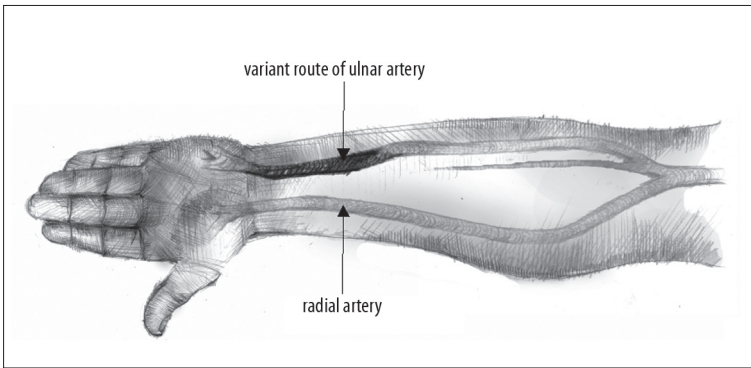


Fig. 2. Atypical route of the ulnar artery

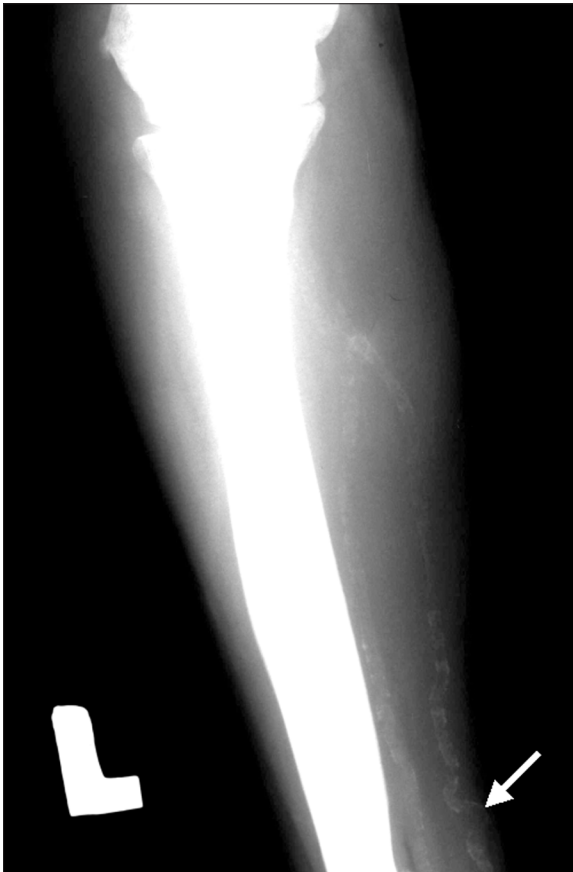


Fig. 3. Superficial ulnar artery with diabetic angiopathy changes (arrow)

before fistula creation it was shown that no vein on the right forearm was available. On the left hand the veins were appropriately filled with blood, but the route of the ulnar artery was altered (Fig. 1, 2). Pulse was present in both the ulnar and radial arteries. Standard Allen test was performed to avoid hand ischemia after arteriovenous fistula creation.

Survey x-ray of both upper limbs allowed viewing both arteries because of the presence of calcium salt deposits (Fig. 3). A rare variant route of the ulnar artery was observed in the wrist region. Instead of a deep route between the muscles, the artery lay superficially. In the distal wrist segment the artery did not only run superficially, but, also untypically, first laterally and then medially. Despite these changes, the surgical procedure was performed in the typical place with the creation of a fistula on the wrist using the radial artery and cephalic vein. The patient did not

present symptoms of hand ischemia. During the follow-up plethysmography (PVR and PG module) of hands and fingers was performed before and after arterio-venous fistula creation to monitor hand's blood supply.

### DISCUSSION

The presented variant route of the ulnar artery involved a patient requiring hemodialysis. Today we know that an arteriovenous fistula on the wrist provides the best vascular access for hemodialysis [6,9]. Anomalies of the arterial system of the upper extremity are well described, but such reports concerning patients with end-stage renal disease are rare [6,15] and we found no report involving the ulnar artery in the wrist region. It is extremely important for patients with end-stage renal disease who require vascular access for renal replacement therapy, i.e. hemodialysis.

An additional difficulty in fistula creation is the intravascular presence of atherosclerosis with calcium deposits. Despite the changes, a flow of 750 ml/min in the fistula during hemodialysis session was achieved and we did not observe symptoms of hand ischemia.

The typical course of the ulnar artery begins distally to the bend of the elbow. It is the superior of the two terminal branches of the brachial artery. Proximally, the artery lies deep to the antebrachial flexor muscles and distally above the flexor retinaculum. Then the ulnar artery forms the superficial palmar arch.

The superficial portion of ulnar artery is usually described as being near the cubital fossa in the proximal segment. Our patient had the superficial portion in the distal third of forearm. In the distal half of the forearm the ulnar artery normally lies between the tendon of the flexor carpi ulnaris and the flexor digitorum superficialis. The described superficial route of the ulnar artery in the distal third of the forearm had a lateral course (Fig. 3). Despite the variant route of the artery, an arteriovenous fistula was created without hand ischemia. Our own experiences demonstrate that even a rare variant route should not be a reason to abandon creation a Cimino-Brescia fistula on the wrist. Standard Allen test is adequate for blood supply checking before fistula creation.

It should also be emphasized that a superficial position of the ulnar artery may be mistaken for veins. Such a wrong interpretation can show the way to intra-arterial injection. A superficial artery is also more vulnerable to trauma. Knowledge of not only a potentially superficial ulnar, but

also radial artery is very important not only for nephrologists, but also for all physicians, surgeons, and nurses [2].

## CONCLUSION

An arteriovenous fistula is extremely important for patients with end-stage renal diseases. Each opportunity for

its creation should be utilized. Even a different route of the artery is not an obstacle to attempting the creation of an arteriovenous fistula on the wrist before creating a fistula in the cubital fossa or catheterizing. We believe that a variant route of the ulnar artery is not a contraindication to the creation of a fistula on the wrist using the radial artery.

## REFERENCES

- [1] Anil A., Turgut H.B., Peber T.V.: A variation of the superficial ulnar artery. *Surg. Radiol. Anat.*, 1996; 215: 82–83
- [2] Chin K.J., Singh K.: The superficial ulnar artery – a potential hazard in patients with difficult venous access. *Br. J. Anaesth.*, 2005; 94: 692–693
- [3] Cohen S.M.: Accidental intra-arterial injection of drugs. *Lancet*, 1948; 255: 409–417
- [4] D'Costa S., Shenoy B.M., Narayana K.: The incidence of a superficial arterial pattern in the human upper extremities. *Folia Morphol. (Warsz)*, 2004; 63: 459–463
- [5] Fadel R.A., Amonoo-Kuofi H.S.: The superficial ulnar artery: Development and surgical significance. *Clin. Anat.*, 1996; 9: 128–132
- [6] Gibson K.D., Caps M.T., Kohler T.R., Hatsukami T.S., Gillen D.L., Aldassy M., Sherrard D.J., Stehman-Breen C.O.: Assessment of a policy to reduce placement of prosthetic hemodialysis access. *Kidney Int.*, 2001; 59: 2335–2345
- [7] Hazlett J.W.: The superficial ulnar artery with reference to accidental intra-arterial injection. *Can. Med. Assoc. J.*, 1949; 61: 289–293
- [8] Jurjus A., Sfeir R., Bezirdjian R.: Unusual variation of the arterial pattern of the human upper limb. *Anat. Rec.*, 1986; 215: 82–83
- [9] Konner K., Hulbert-Shearon T.E., Roys E.C., Port F.K.: Tailoring the initial vascular access for dialysis patients. *Kidney Int.*, 2002; 62: 329–338
- [10] Rodríguez-Baeza A., Nebot J., Ferreira B., Reina F., Pérez J., Sañudo J.R., Roig M.: An anatomical study and ontogenetic explanation of 23 cases with variations in the main pattern of the human brachio-antebrachial arteries. *J. Anat.*, 1995; 187: 473–479
- [11] Rodríguez-Niedenführ M., Burton G.J., Deu J., Sañudo J.R.: Development of the arterial pattern in the upper limb of staged human embryos: Normal development and anatomic variations. *J. Anat.*, 2001; 199: 407–417
- [12] Rodríguez-Niedenführ M., Vázquez T., Nearn L., Ferreira B., Parkin I., Sañudo J.R.: Variations of the arterial pattern in the upper limb revisited: a morphological and statistical study, with a review of the literature. *J. Anat.*, 2001; 199: 547–566
- [13] Rodríguez-Niedenführ M., Vázquez T., Parkin I.G., Sañudo J.R.: Arterial patterns of the human upper limb: Update of anatomical variations and embryological development. *Eur. J. Anat.*, 2003; 7: 21–28
- [14] Wandzilak M., Bodzoń W., Krzanowski M.: Brachiocephalic vein confluence stenosis treated by two Wallstents using “Y” technique. *Med. Sci. Monit.*, 2004; 10: 123–126
- [15] Weyde W., Krajewska M., Penar J., Bartosik H., Klinger M.: Vascular abnormalities in patients with autosomal dominant polycystic kidney disease—the influence on arteriovenous fistula creation. *Clin. Nephrol.*, 2004; 61: 344–346
- [16] Weyde W., Krajewska M., Zmonarski S.C., Letachowicz W., Penar J., Watorek E., Golebiowski T., Kusztal M., Dubinski B., Badowski R., Garcarek J., Madziarska K., Klak R., Klinger M.: The abnormal superficial radial artery does not restrict the successful creation of hemodialysis forearm arteriovenous fistula. *Clin. Nephrol.*, 2009; 71: 584–587

The authors have no potential conflicts of interest to declare.